



Pediyatrik Toraks Görüntülemesi

Çocuk Göğüs Hastalıklarında Tanısal Yaklaşımlar Kursu

Dr Hüdaver Alper

Ege Üniversitesi Tıp Fakültesi
Radyoloji Anabilim Dalı
Pediyatrik Radyoloji Bilim Dalı

Pediatric Toraks Görüntülemesi

AMAÇ

Tetkik yöntemlerinin zararlarını
vurgulamak,

Akciğer grafilerine anlayarak bakmanıza,

Radyolojik inceleme yöntemleri arasında
öncelikleri belirleyebilmenize

.....yardımcı olmak

Sunum Akışı

Görüntülemenin Zararları

Normal Toraks Anatomisi

Mediasten

Akciğer vaskülaritesi

Akciğer parankimi

Plevra ve diafragma

Toraks duvarı

Radyolojik Yöntemlerin Zararları

İnsanlarda yaşam boyu tüm kanser riskinin % 10 kadarı tanısal radyolojik yöntemlerde alınan radyasyona bağlı

Risk of cancer from diagnostic x-rays: estimates for the UK and 14 other countries . Amy Berrington de González, Sarah Darby , *The Lancet*, Volume 363, Issue 9406, 31 January 2004, Pages 345-351

Tartışıldı, kanıtlanması zor bir iddia

X – Işınları canlılara zararlı

Bebek ve çocukların gelişmekte olan dokularında çok daha fazla zararlı

Bu nedenle Radyasyon İçeren Tetkikler endikasyon dışı istenmemelidir.

Tetkik isterken Őu soruları cevaplamalıyız

1. Bu tetkik dűşündüğümüz hastalığı (tanıyı) ortaya koyabilecek en iyi tetkik midir?
2. Elde edilen bilgi tedavi amacımıza yeterli midir? (amacımızı aşabilir mi?)
3. Hastaya zarar verebilir mi? Elde edilecek bilgi bu zararı göze almaya değer mi ?

ALARA

Radyasyon zararlarının asgariye indirilmesi

ALARA = **A**s **L**ow **A**s **R**easonably **A**chieveable

ALARA Hastaya yararlı bilgileri elde edebileceğimiz en düşük radyasyon dozunu vermeyi hedefler

Asgari sayıda radyolojik tetkik

Her radyolojik tetkikte mümkün olan asgari X ışını

MRG Endikasyonları

Hastanız uzun tetkik sürelerini kaldırabiliyorsa..

Solunum ve Kalp atımı tetiklemesi yapılabilirsa...

Cihaz ve Hasta yanibaşında

Anestezi Uzmanı ve cihazı

Radyoloji Uzmanı bulunabiliyorsa...

MRG tetkiki istemeyi düşünebilirsiniz

BT Endikasyonları

Yenidoğanın kardio-vasküler anomalileri (*)

Akciğerin anormal gelişimleri

Bronşektazi

Bazı enfeksiyonlar

İnterstisyel hastalıklar

Toraks tümörleri ve evrelemesi

Başka türlü çözülemeyen görüntüler

ULTRASON Endikasyonları

Yenidoğanın kardio-vasküler anomalileri (*)

Tek taraflı opak akciğer

Toraks duvarına bitişik opasiteler

Plevral effüzyon

Plevral hastalıklar

Akciğer Grafisi

En yoğun olarak kullanılan görüntüleme yöntemi

Tüm akciğer alanını kapsama

Uzaysal ayrıştırma

Ucuz

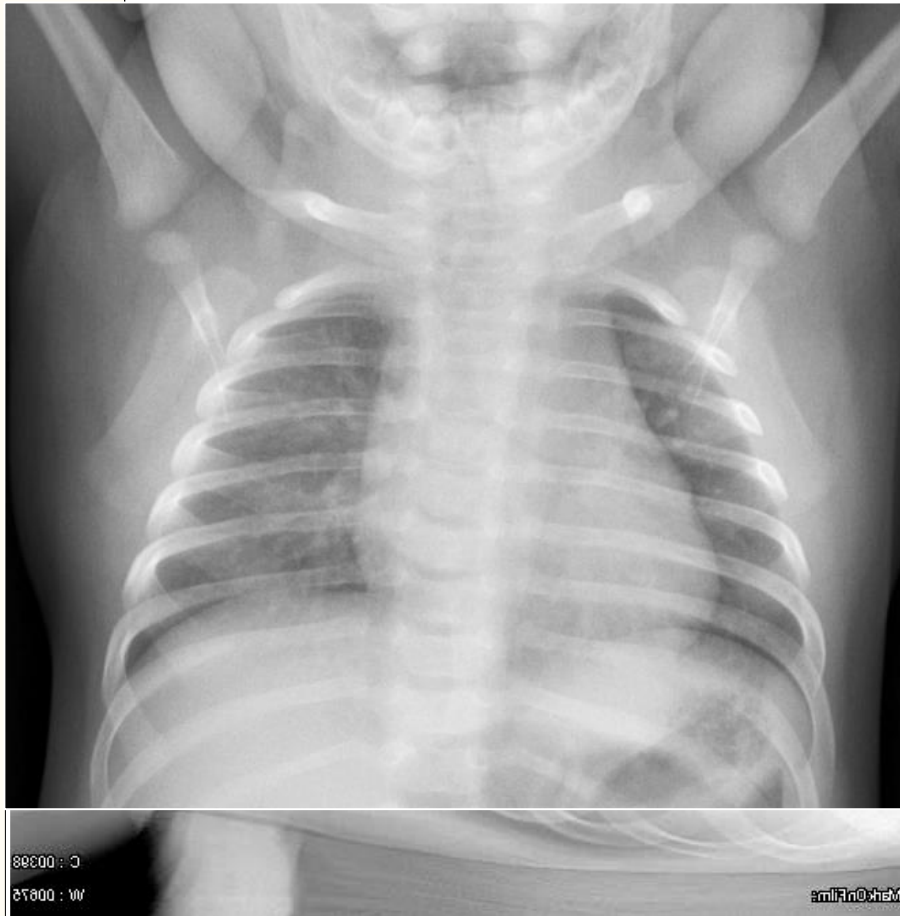Tekrarlanabilir *

İki boyutlu *

Mediasteni sadece kontur olarak tanımlayabilir

Renk ayırımı beş ile kısıtlıdır

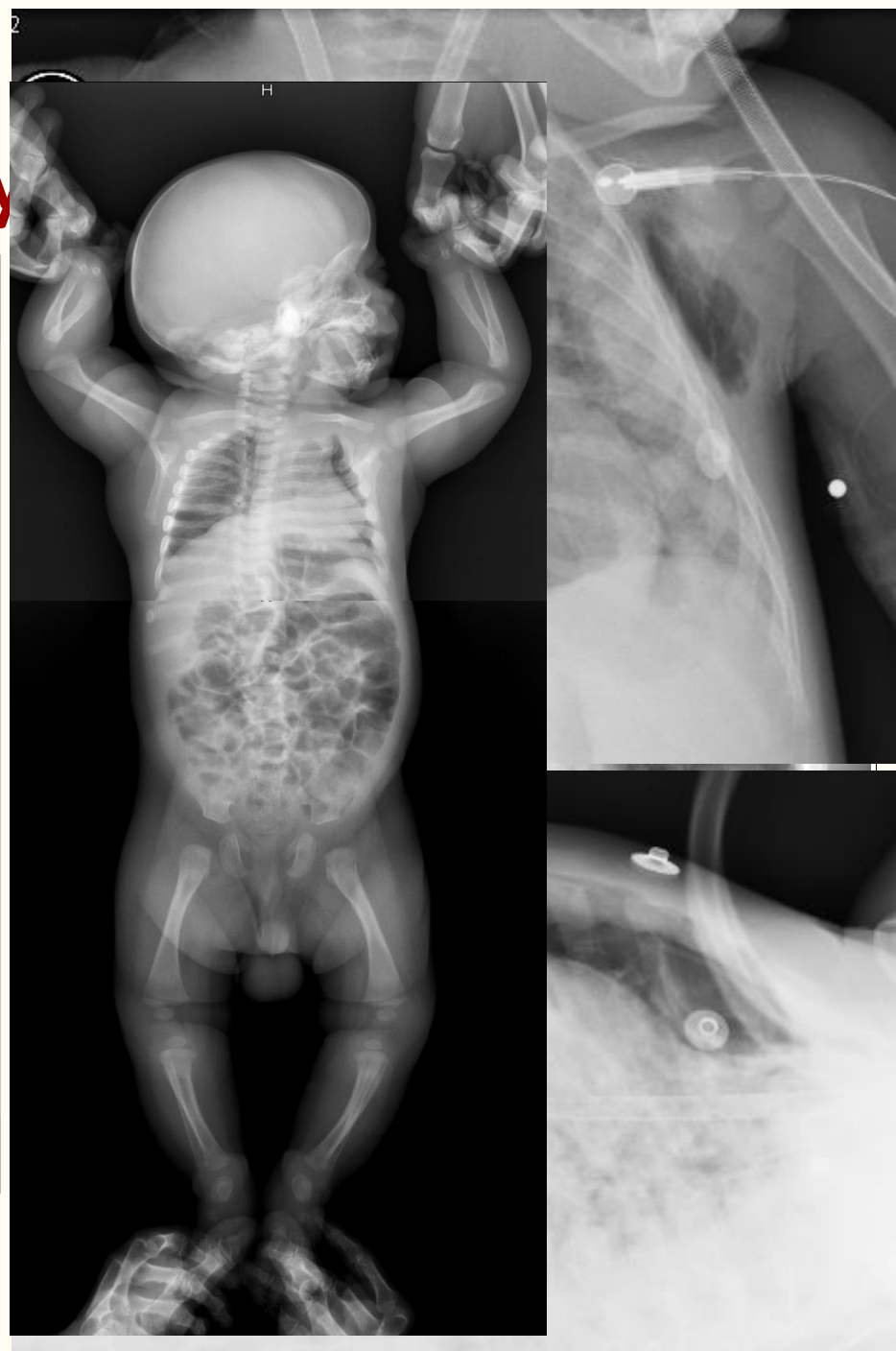Pozisy



00000 : C
00000 : W

amifinO chetV

«Cross-Table»



Normal Nedir ?

Tanımlanmış bir standarda, kurala yada prensibe uyan

Bir türe, standarda veya şekle sahip olan,

Normal fonksiyonlar gösteren

Anormal olmayan

Alışıl gelmiş

Tabii

Analojik

Normal Pediatrik Akciğer

Çocuk akciğeri için standard bir normal tanımı yapmak zor

Yaş

Solunum fazı

Postür

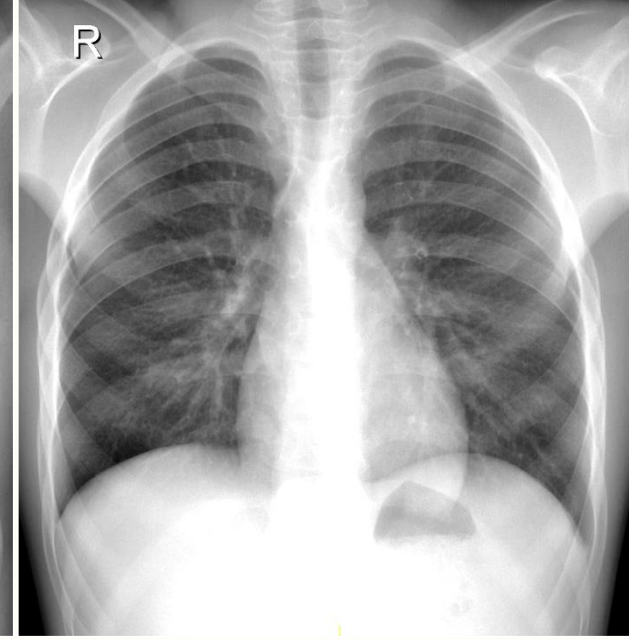
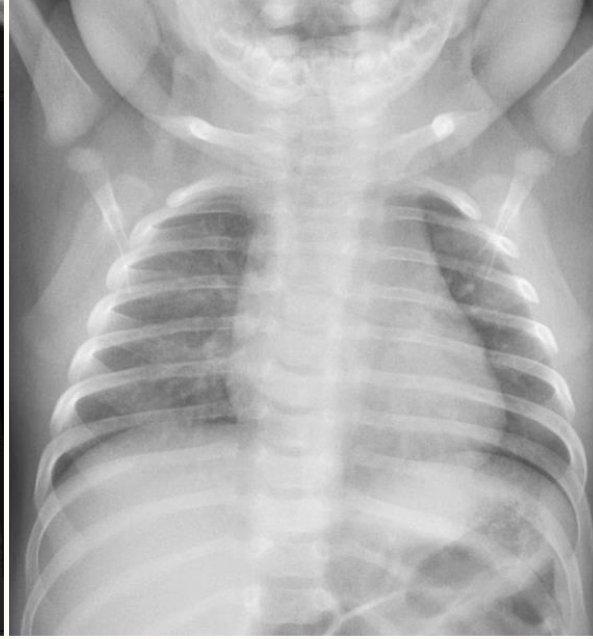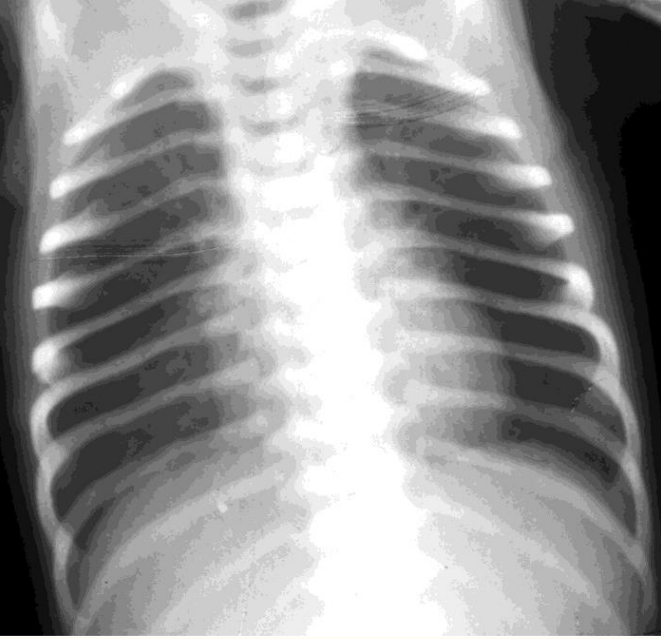
Varyasyonlar

Normalin çok çeşitli şekillerde karşımıza çıkmasına yol açmakta

Yenidoğan

Enfant

4 yaş üzeri



Yüksek intrauterin
pulmoner basınç
nedeniyle

VASKÜLARİTE ↓

Hiluslar ve vasküler yapılar
normale dönmüştür

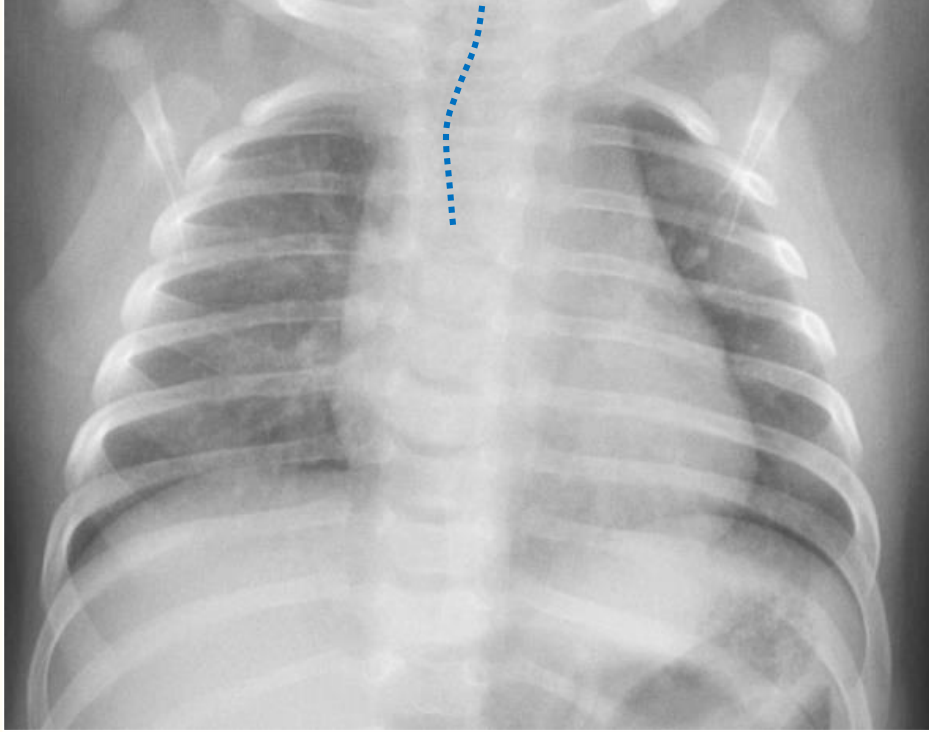
Mediasten timus nedeniyle
geniştir

Mediastinal normal
konturların bir kısmı timus
nedeniyle silinmiştir

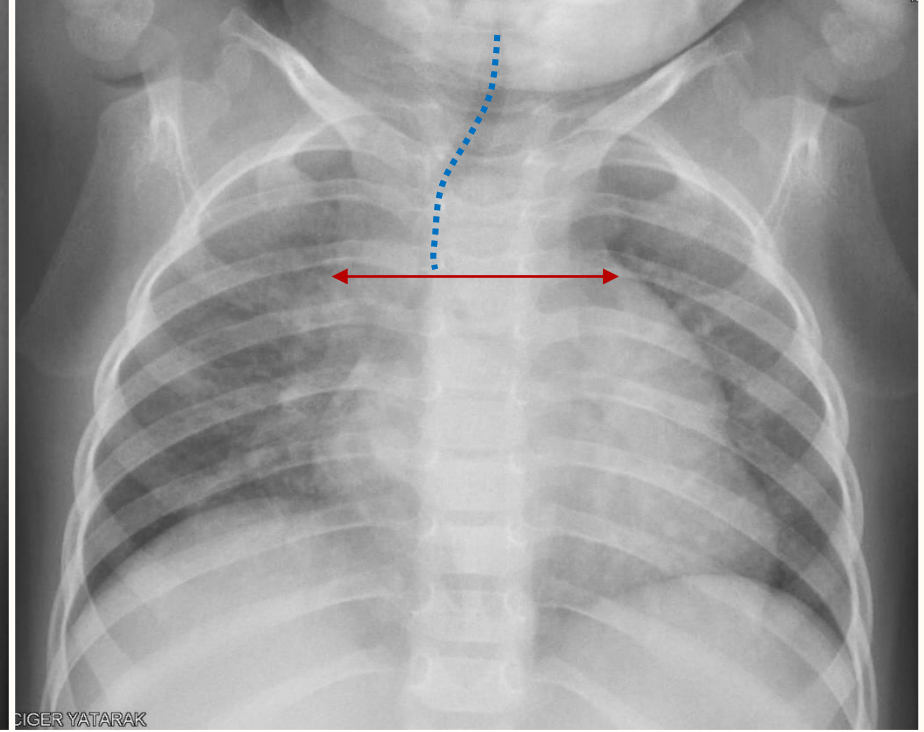
Solunum fazı en çok bu
yaşta normal etkiler

Erişkin Akciğerine
benzer

Solunum Fazları

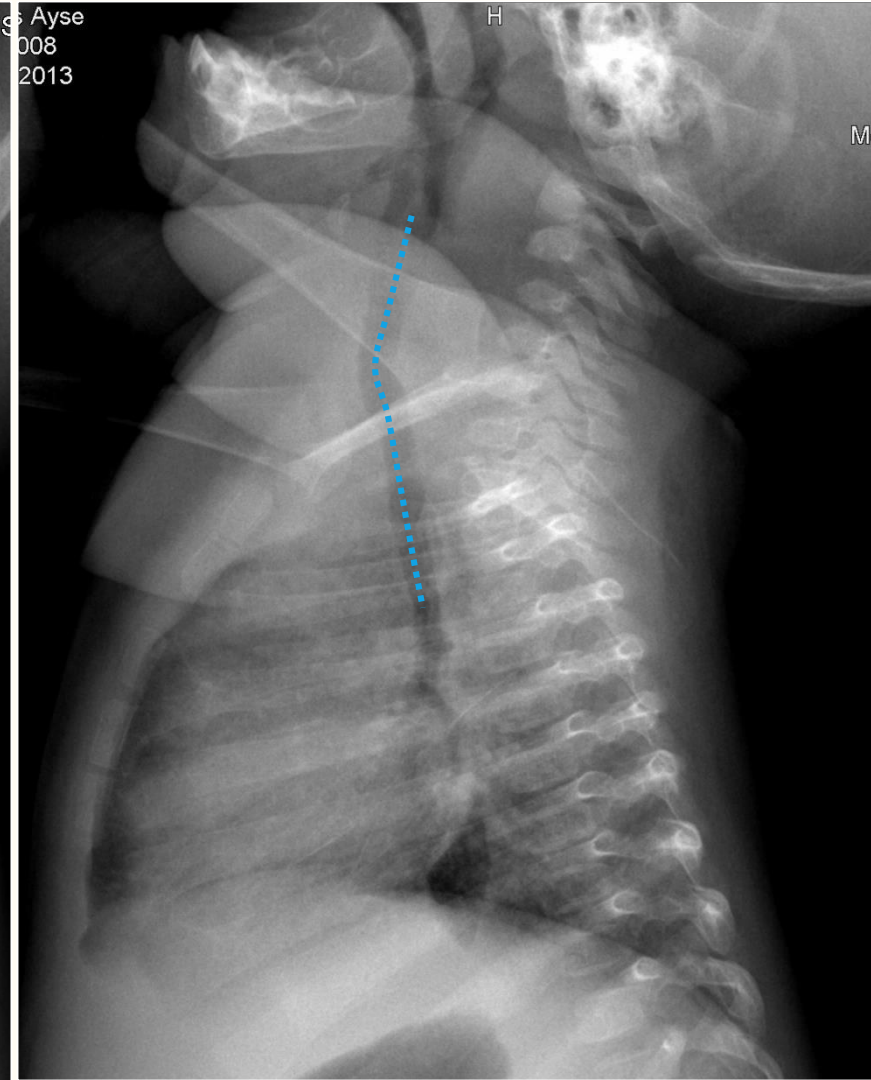
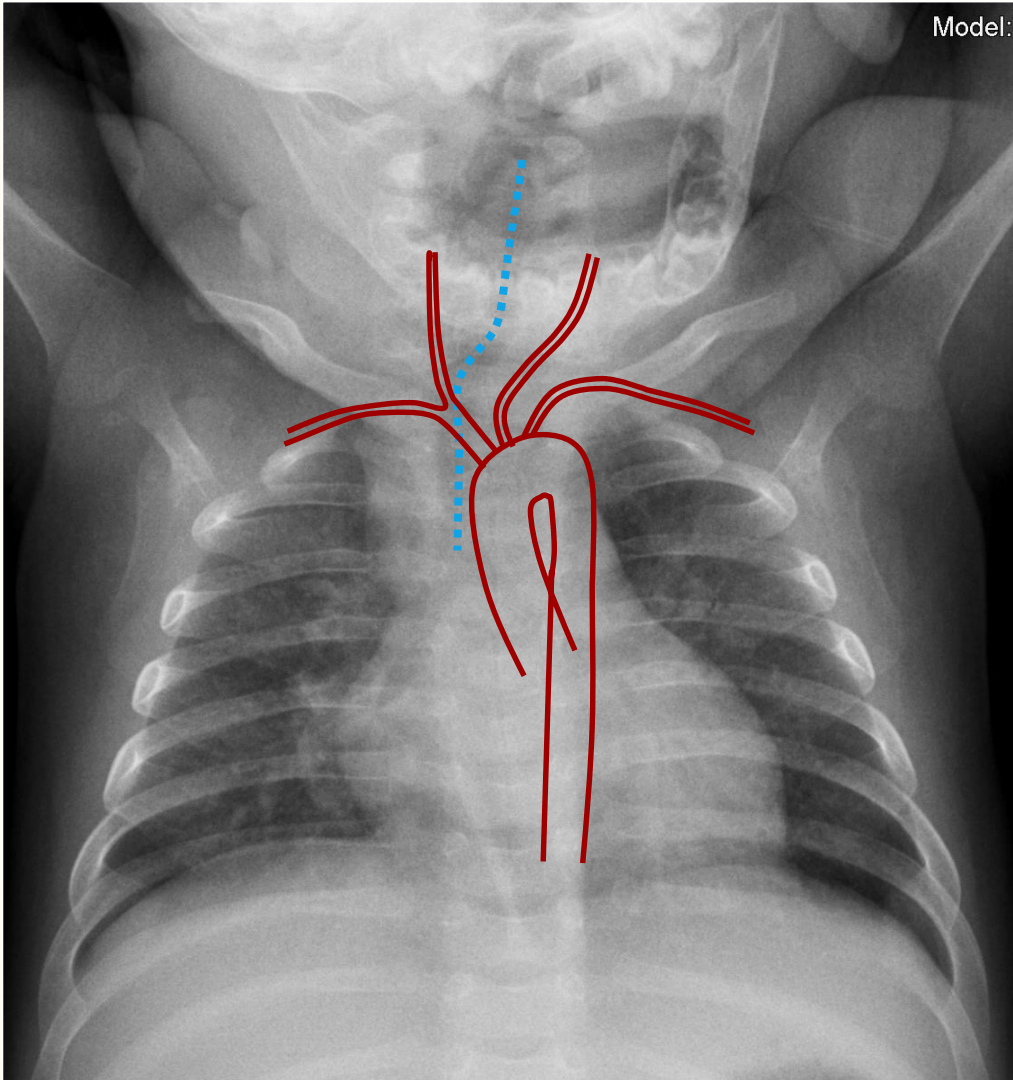


inspiryum

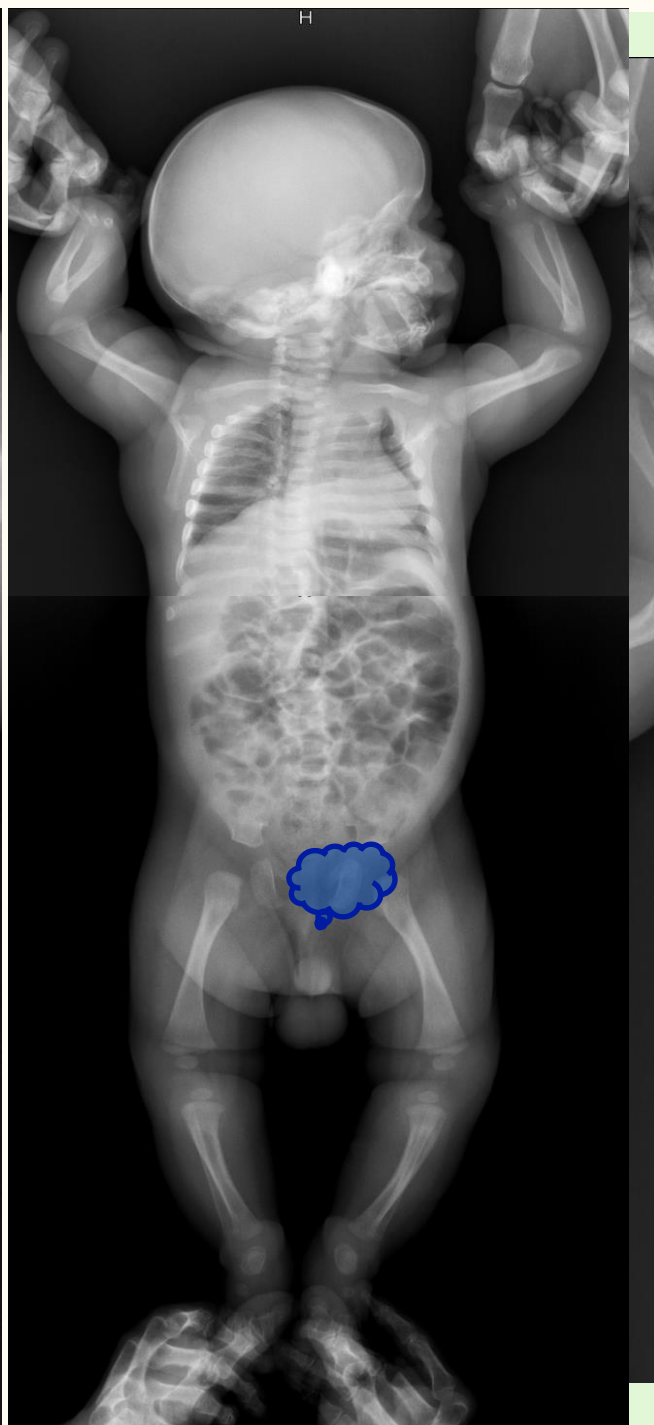
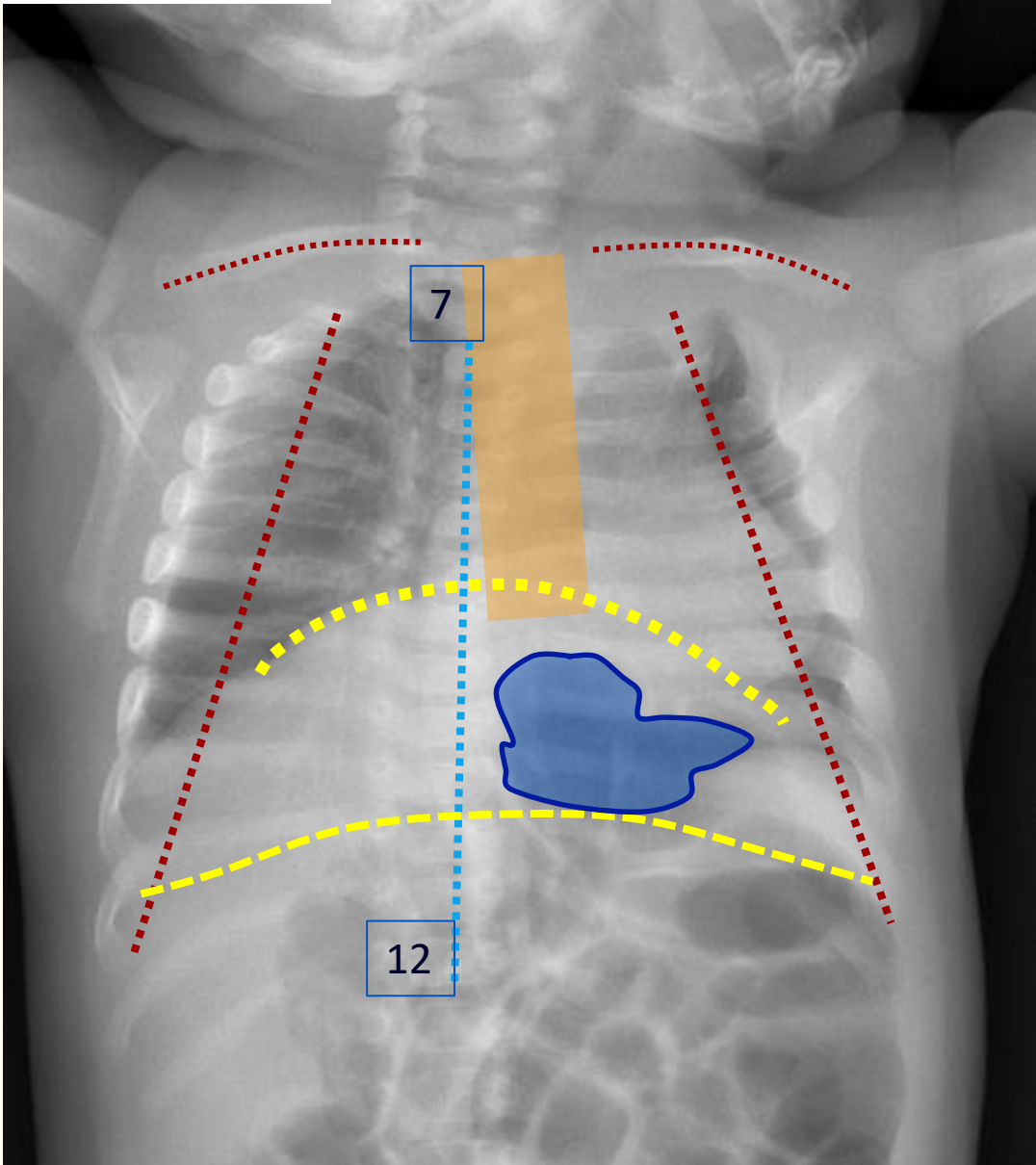


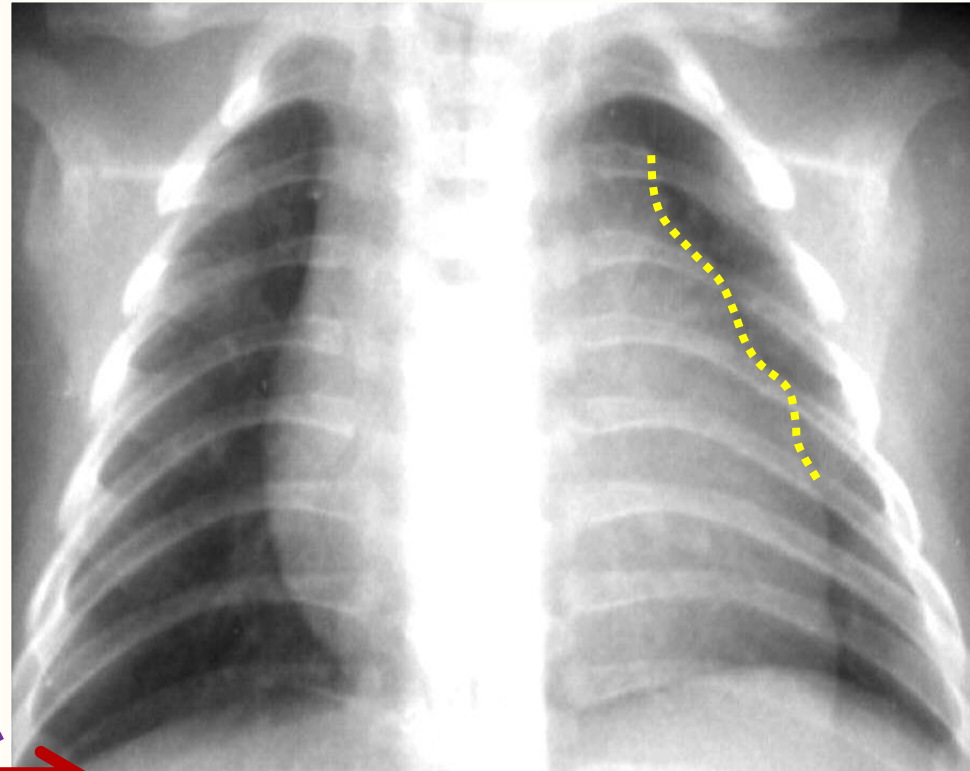
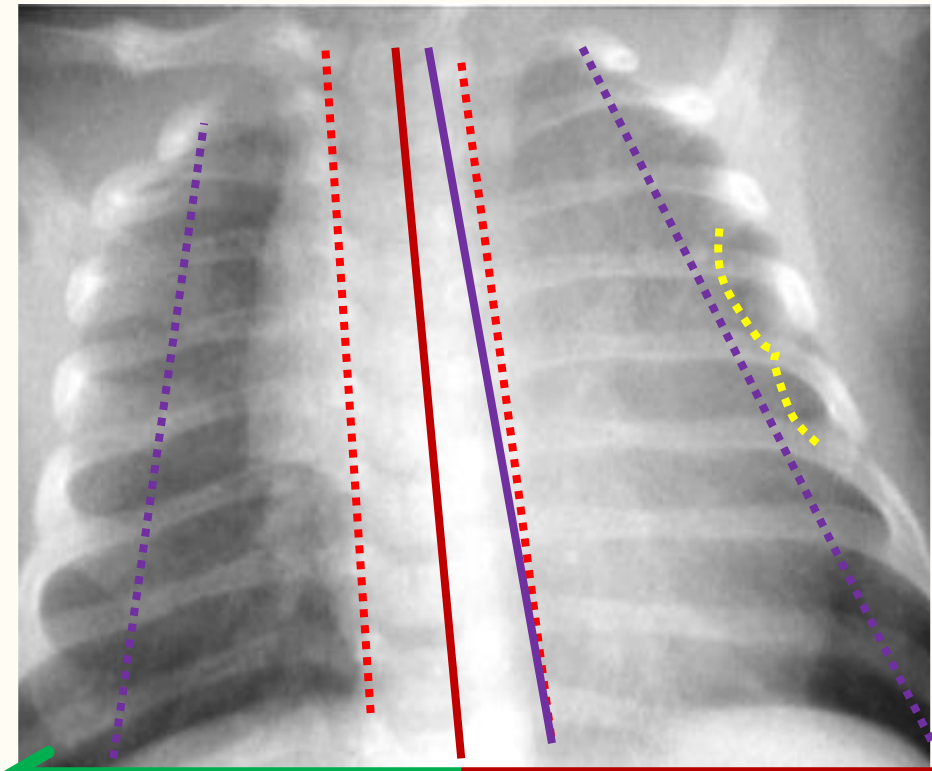
ekspiryum

Trakeal «Buckling»



Postür

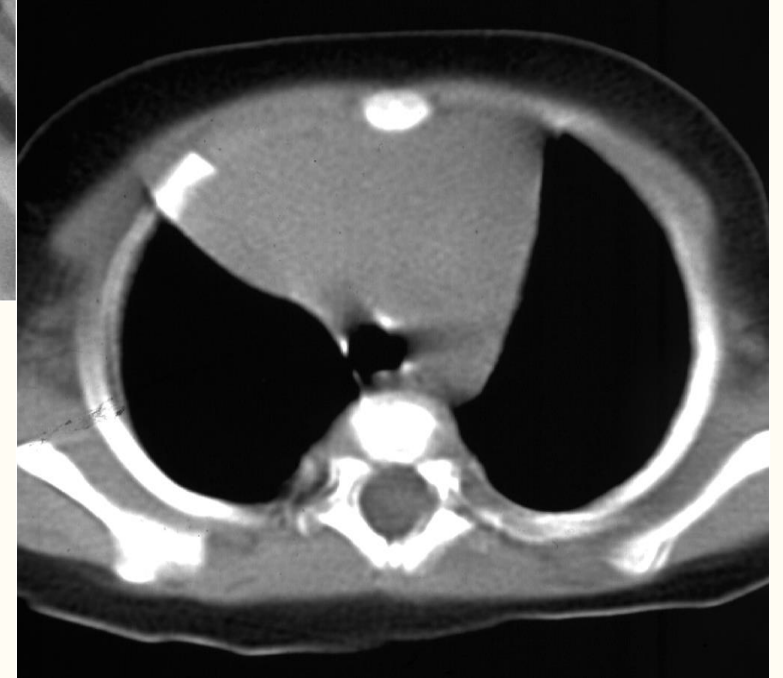
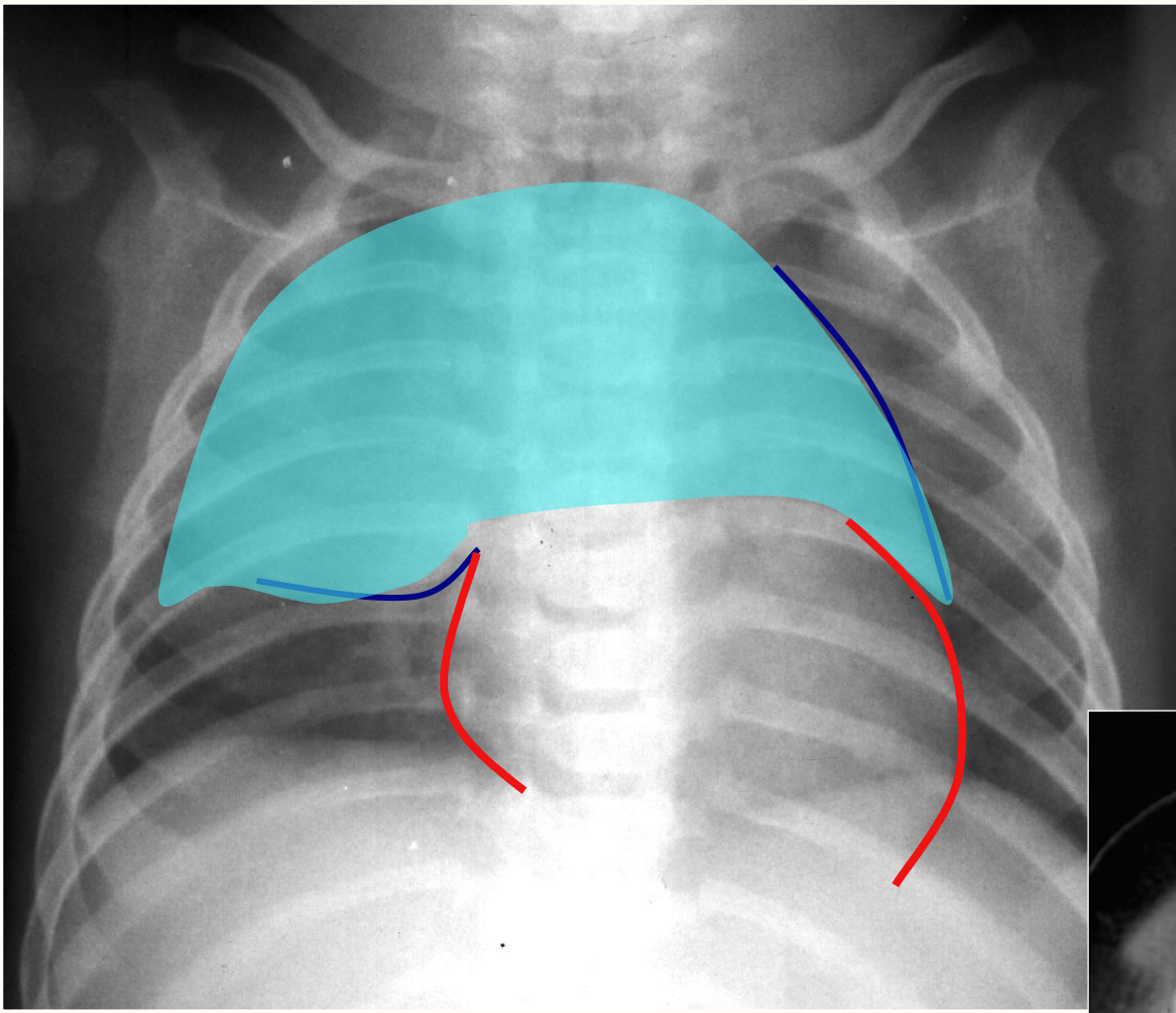




Timus

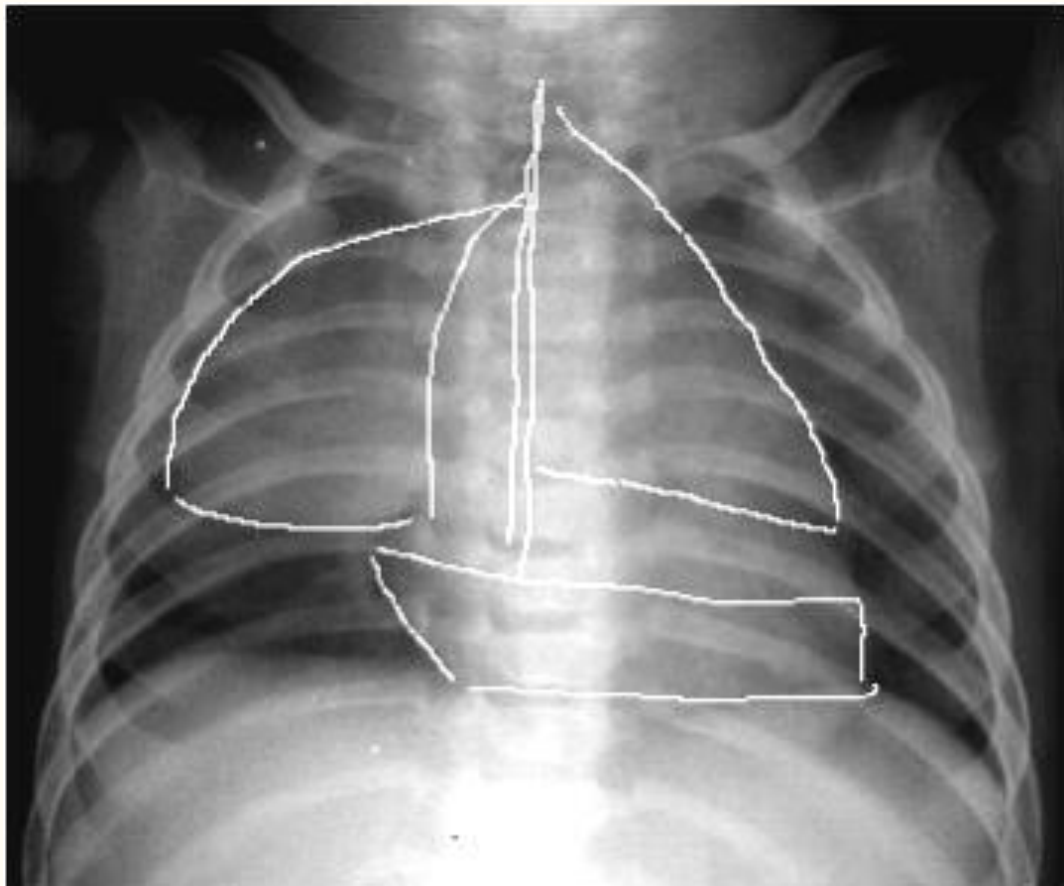
«Thymic Wave Sign»

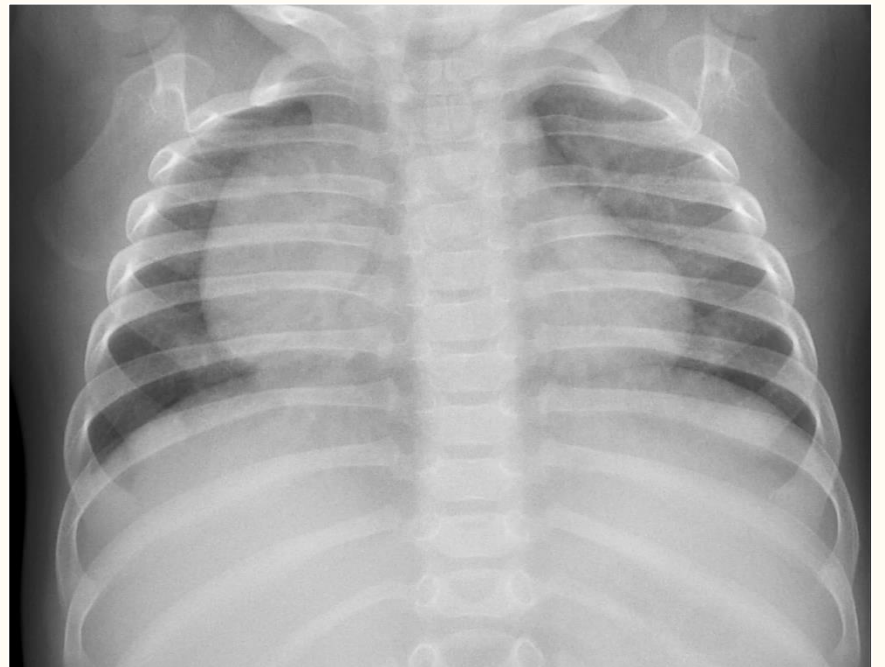
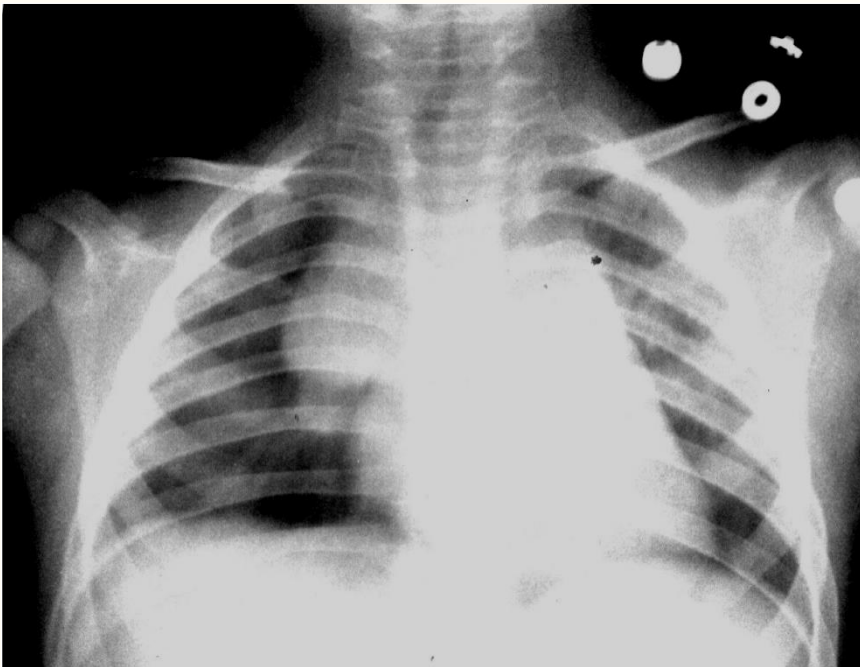
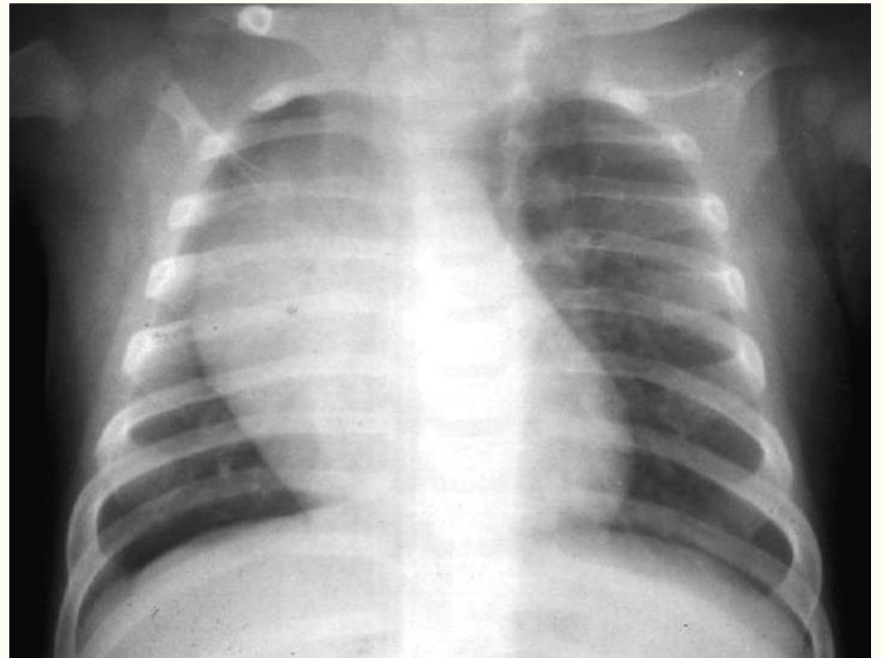
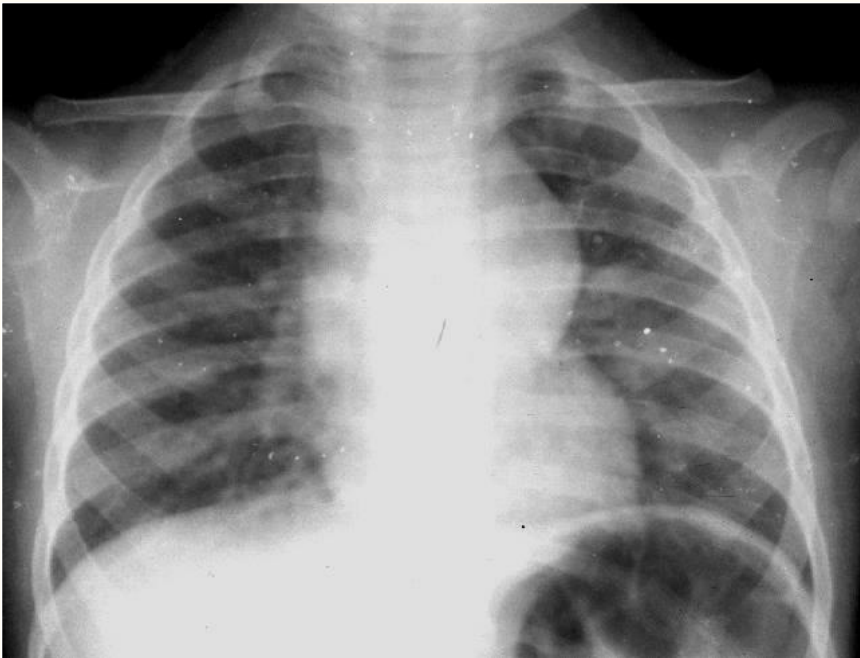
Timus



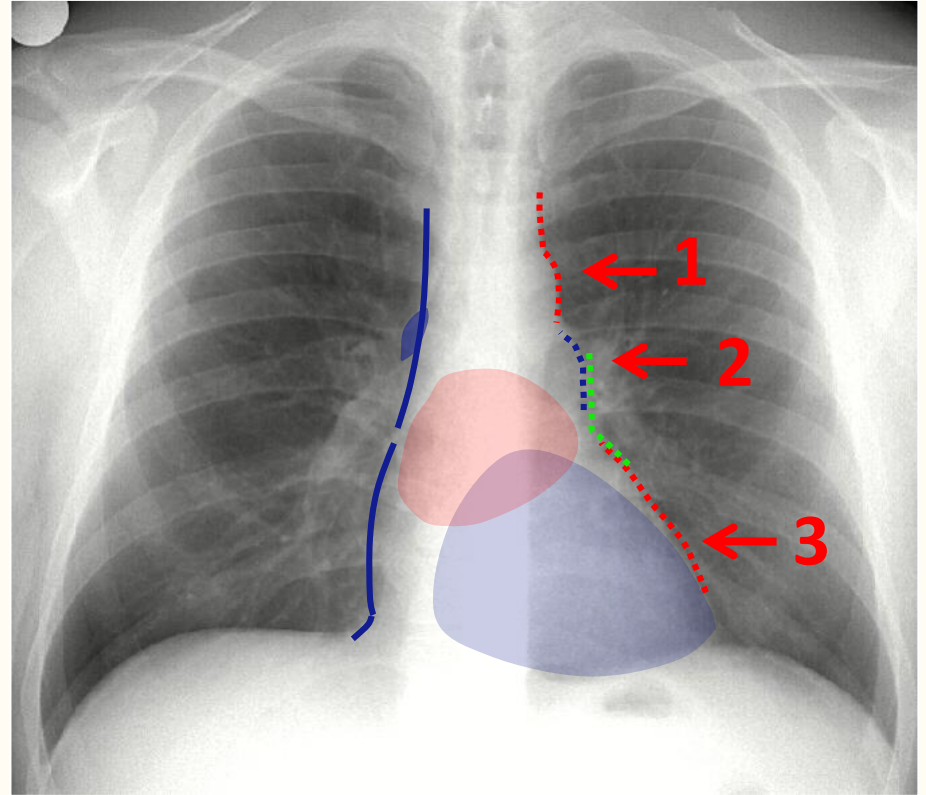
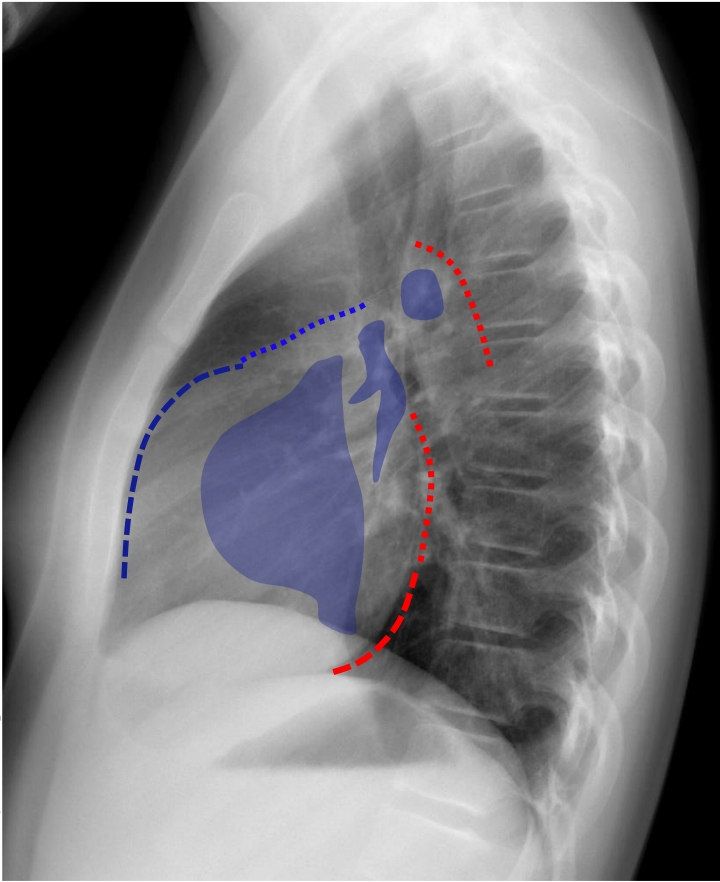
Acil servise ateş ve huzursuzlukla gelmiş

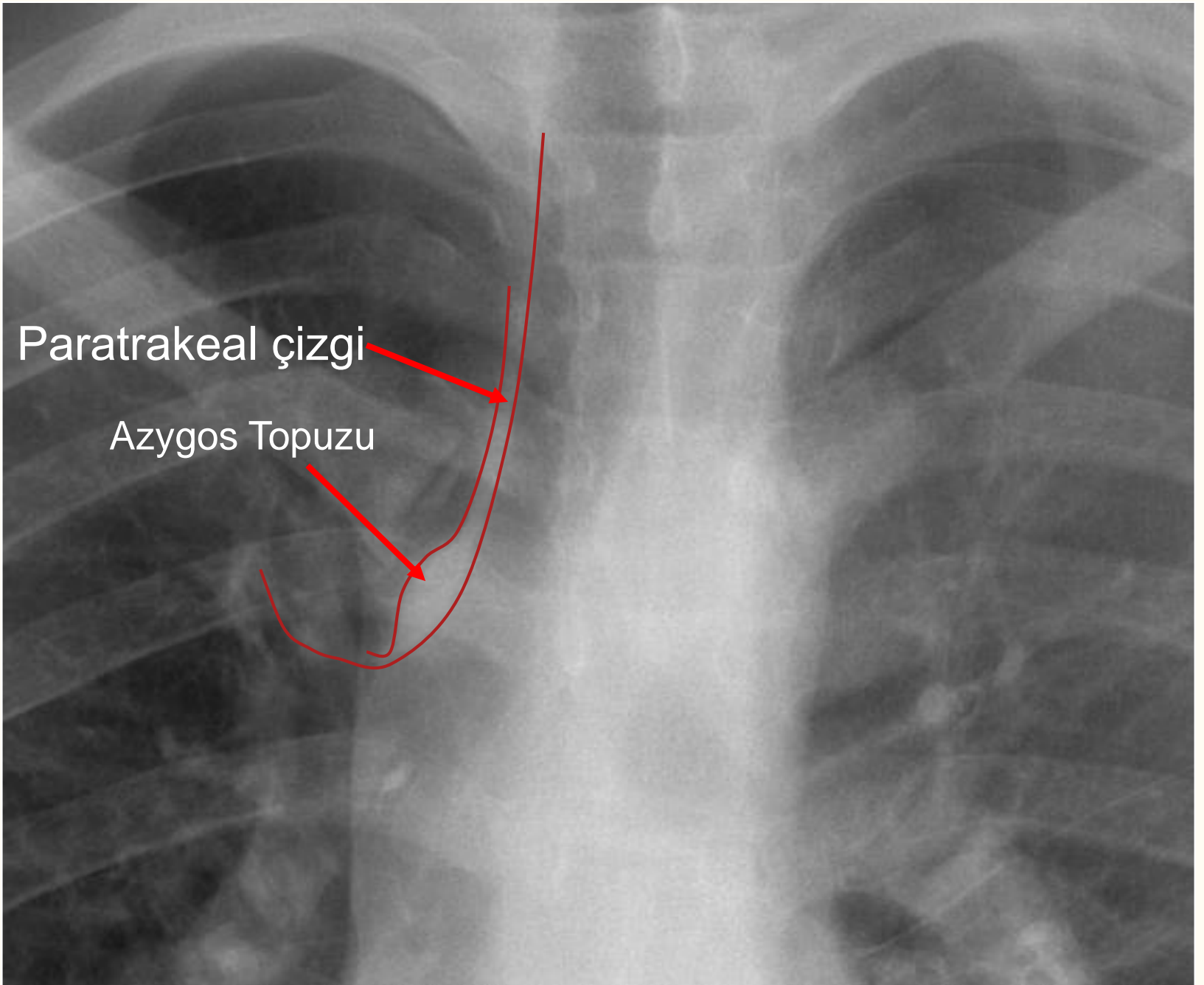
Bu grafi görülünce pnömoni tanısıyla antibiyoterapi başlanmış





Mediastinal Kenarlar ve KVS





Paratrakeal çizgi

Azygos Topuzu

Std:1627472

ImNo:1

RefPhys:

AcqDt:10.09.2012

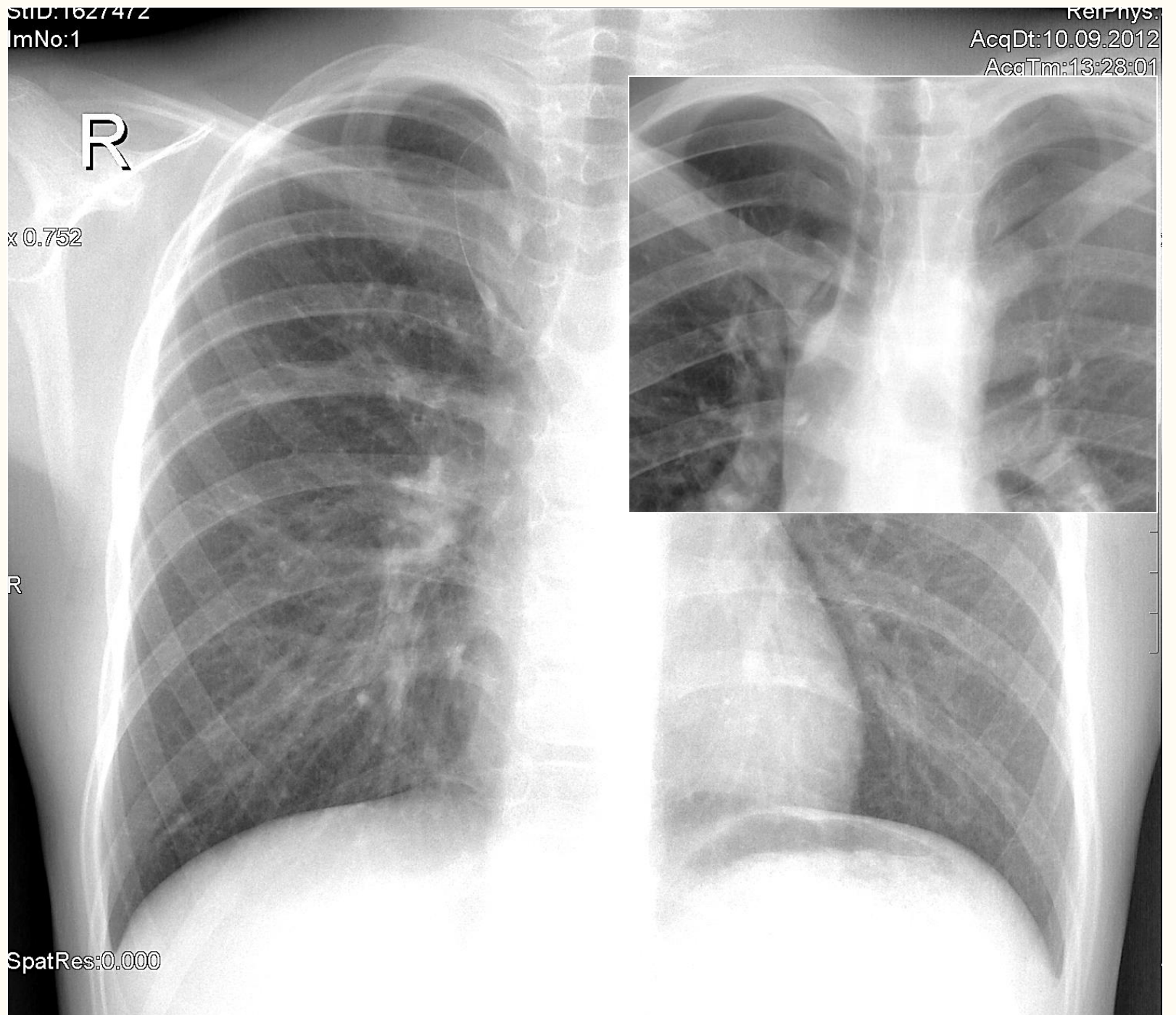
AcqTm:13:28:01

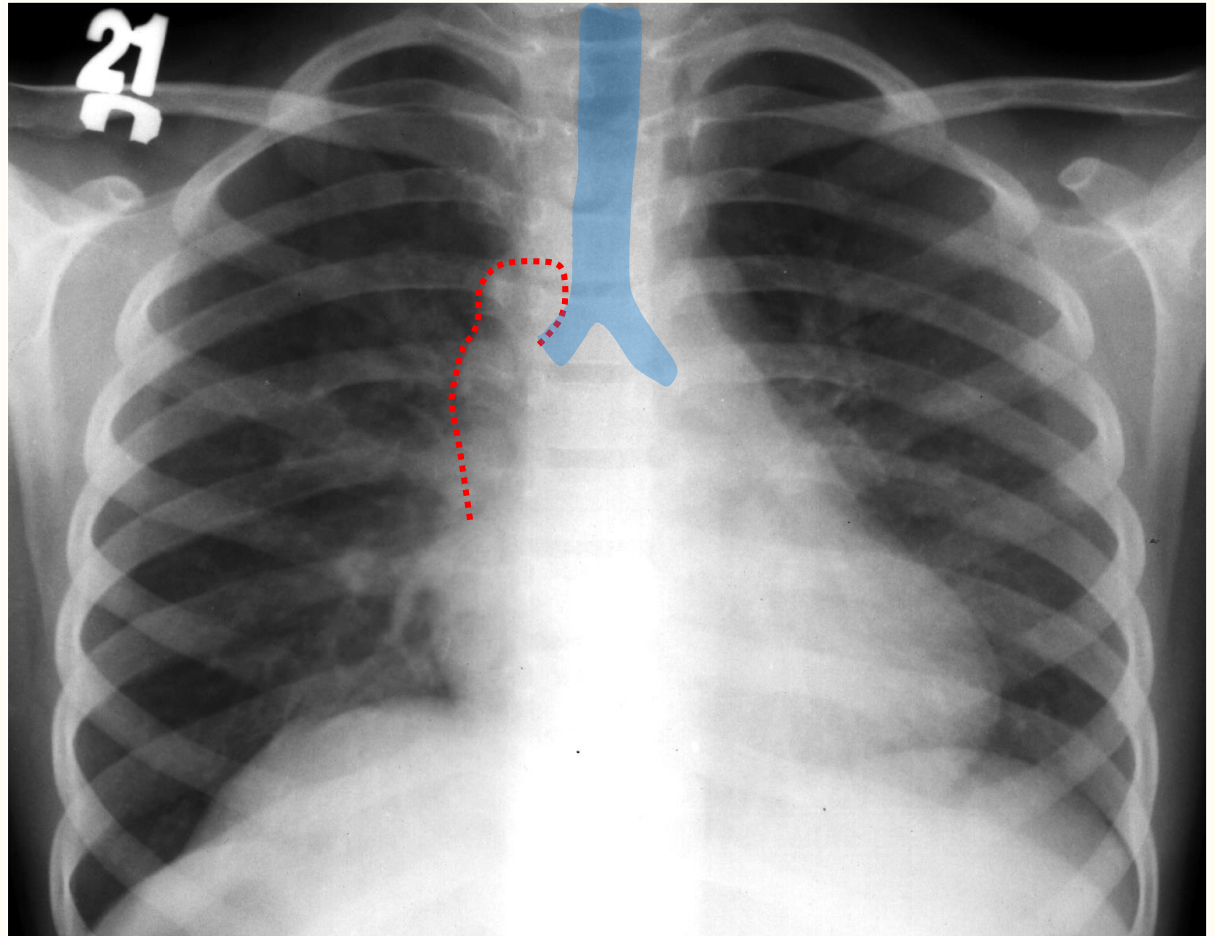
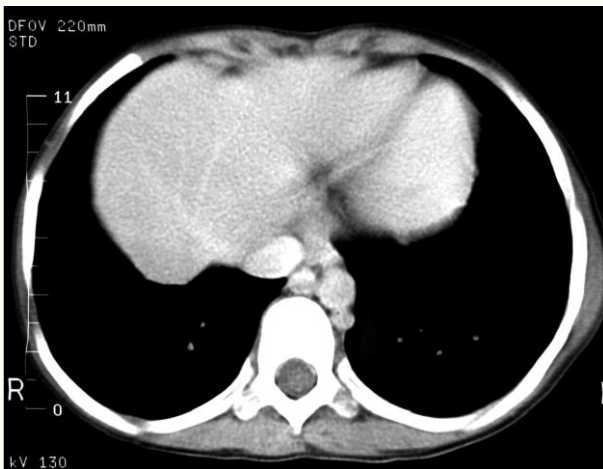
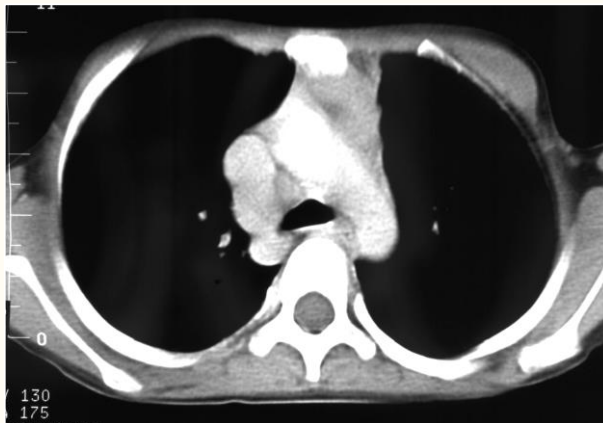
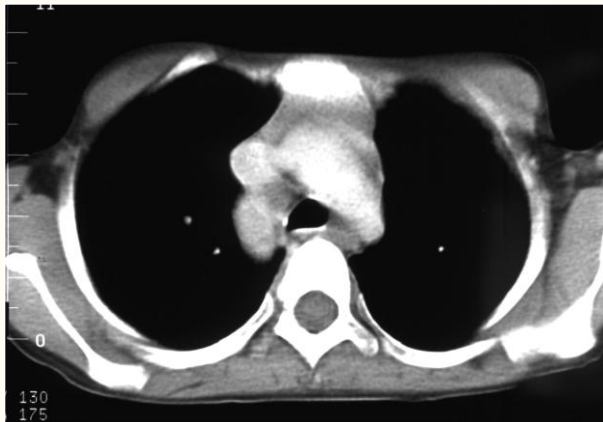
R

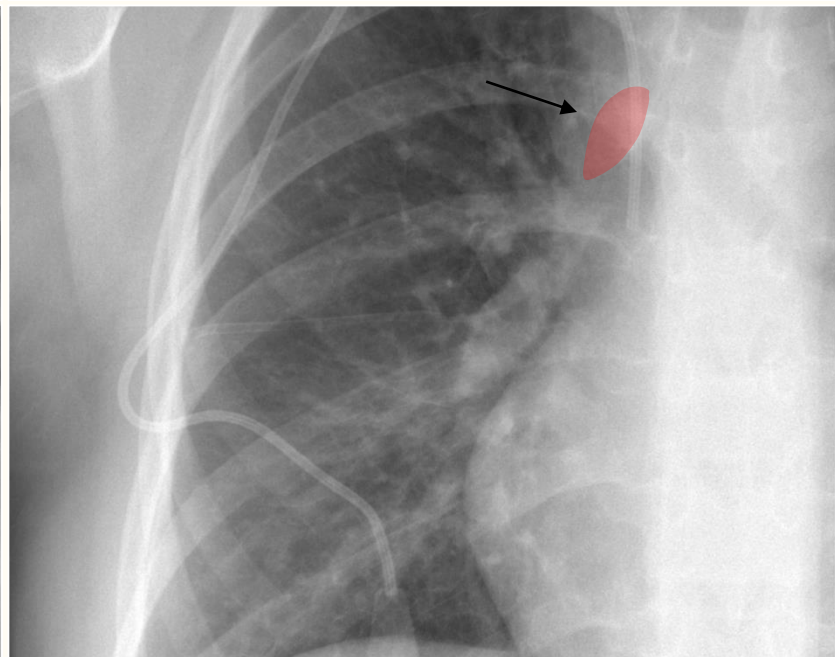
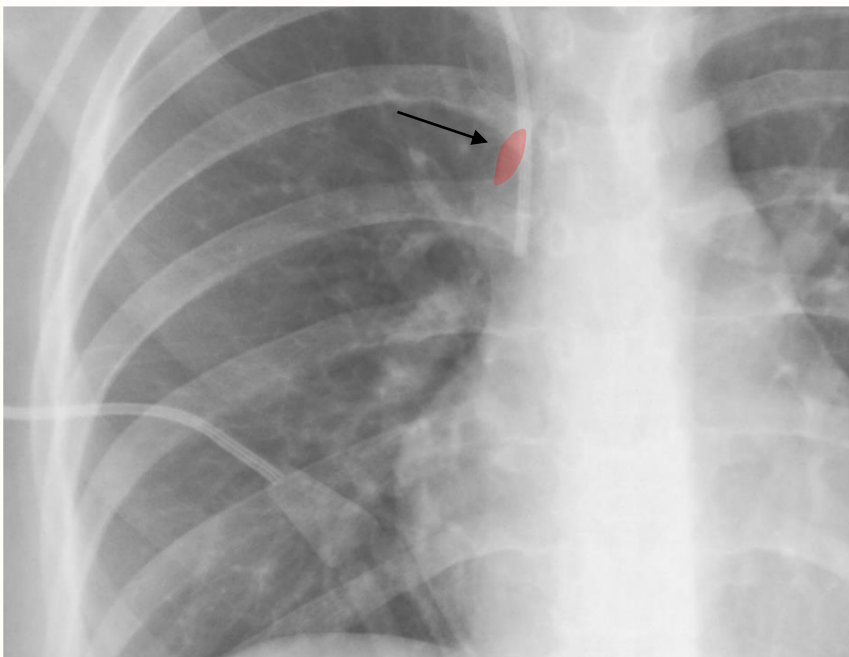
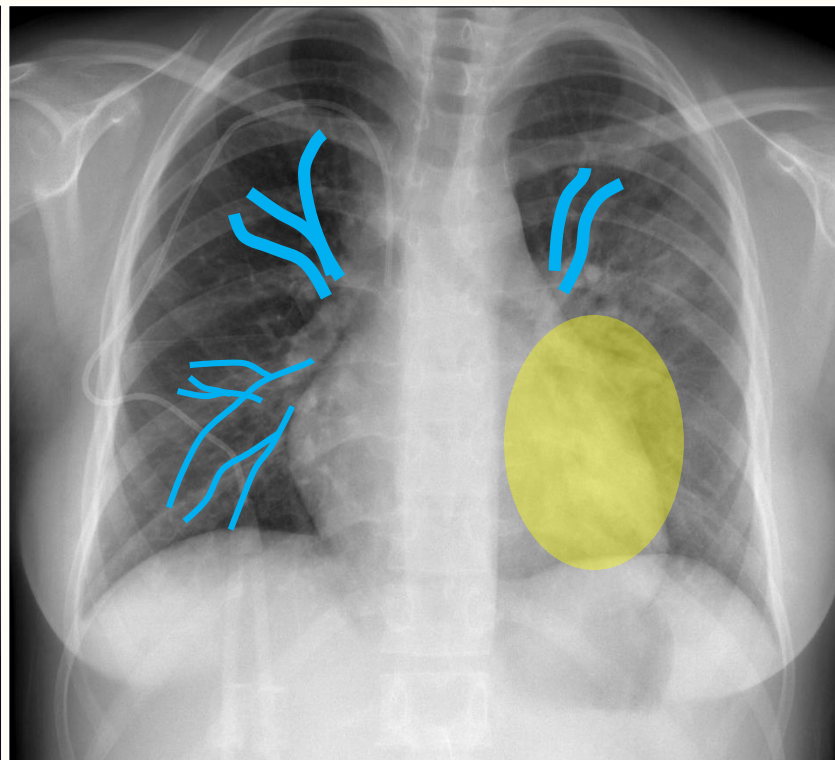
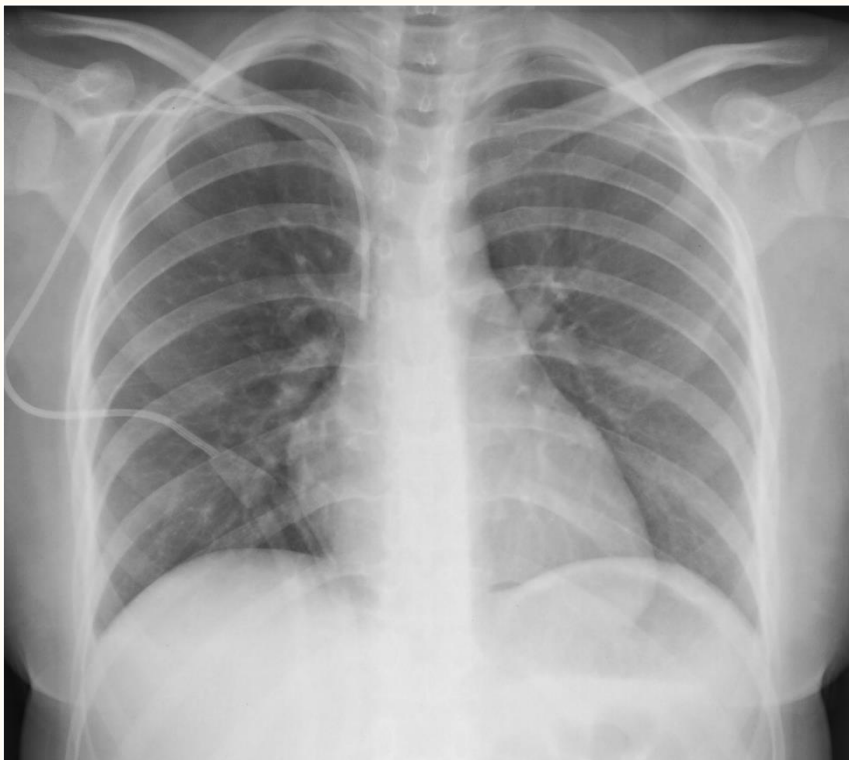x 0.752

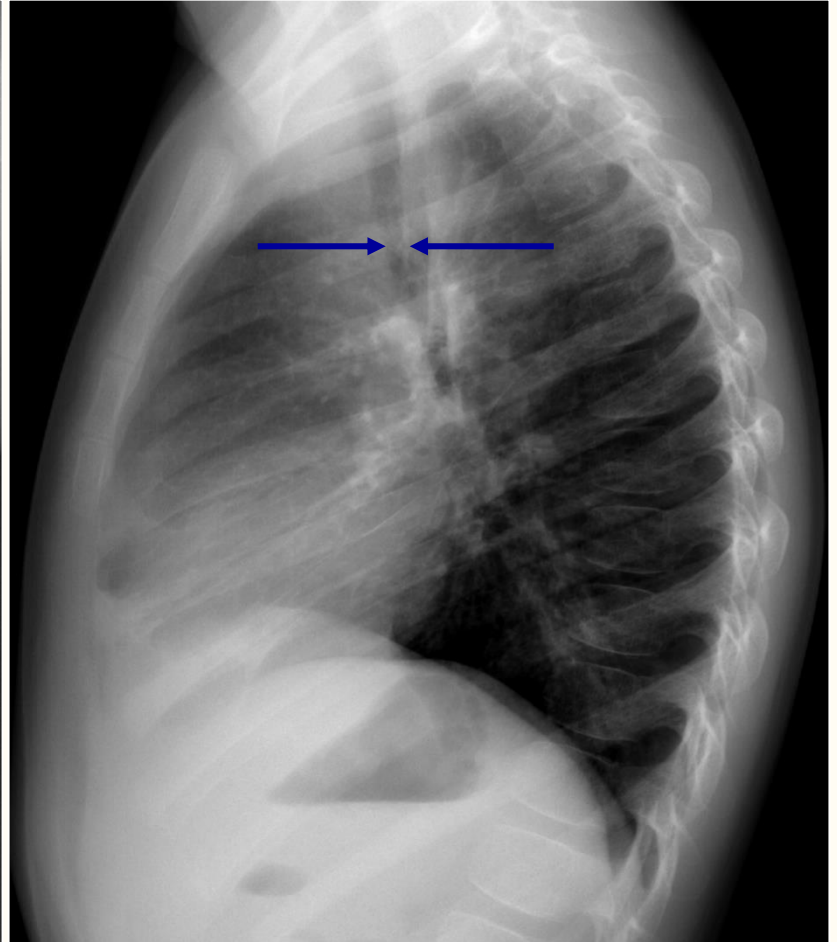
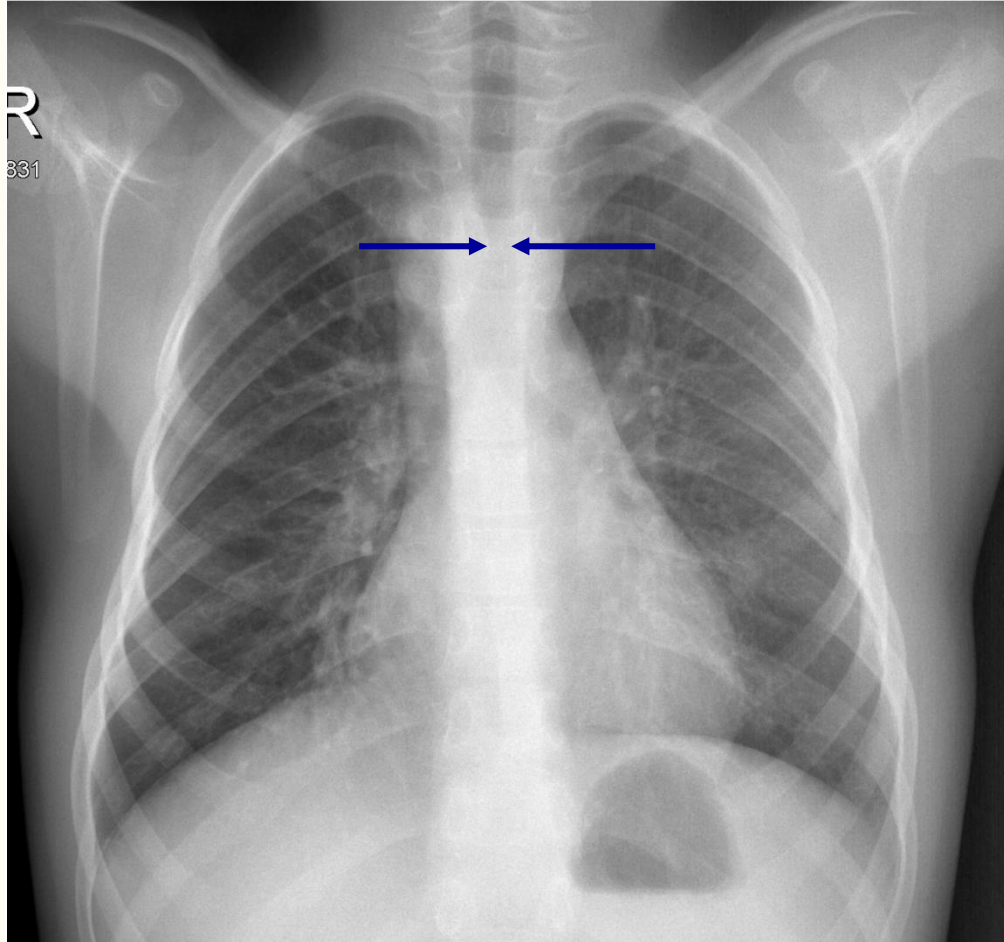
R

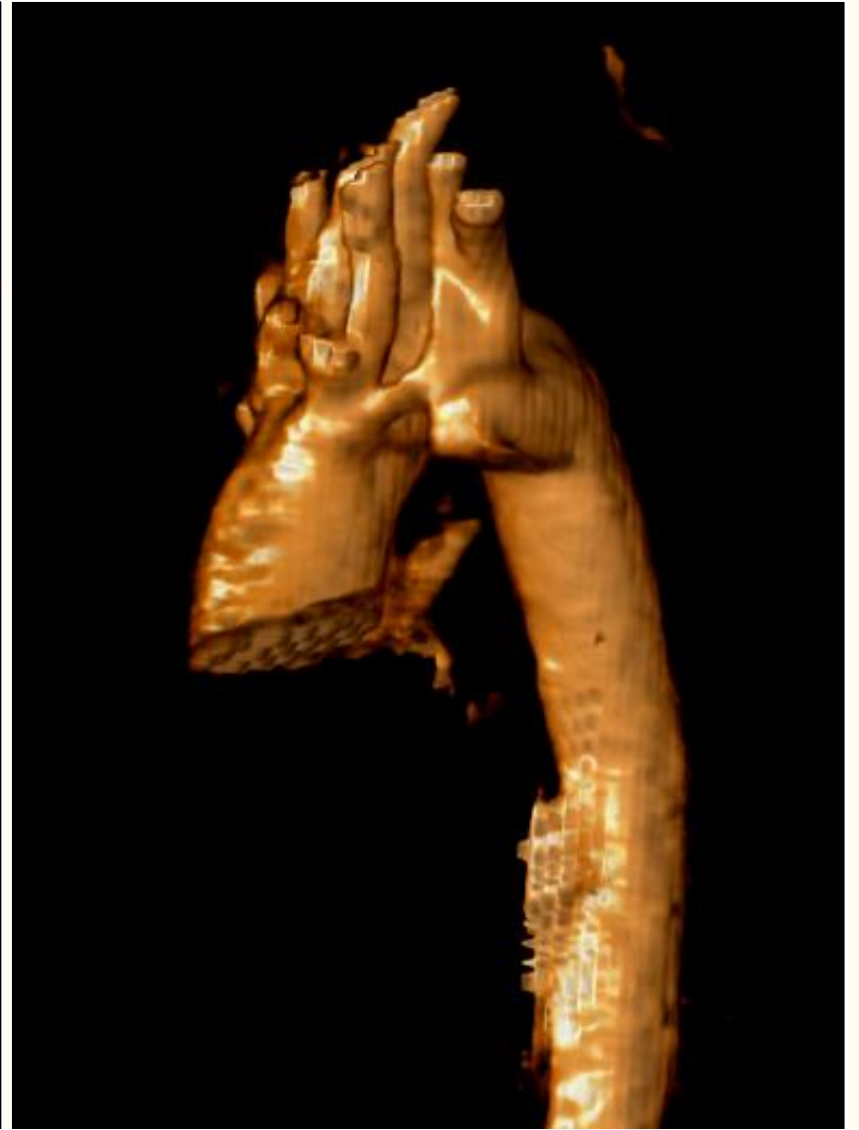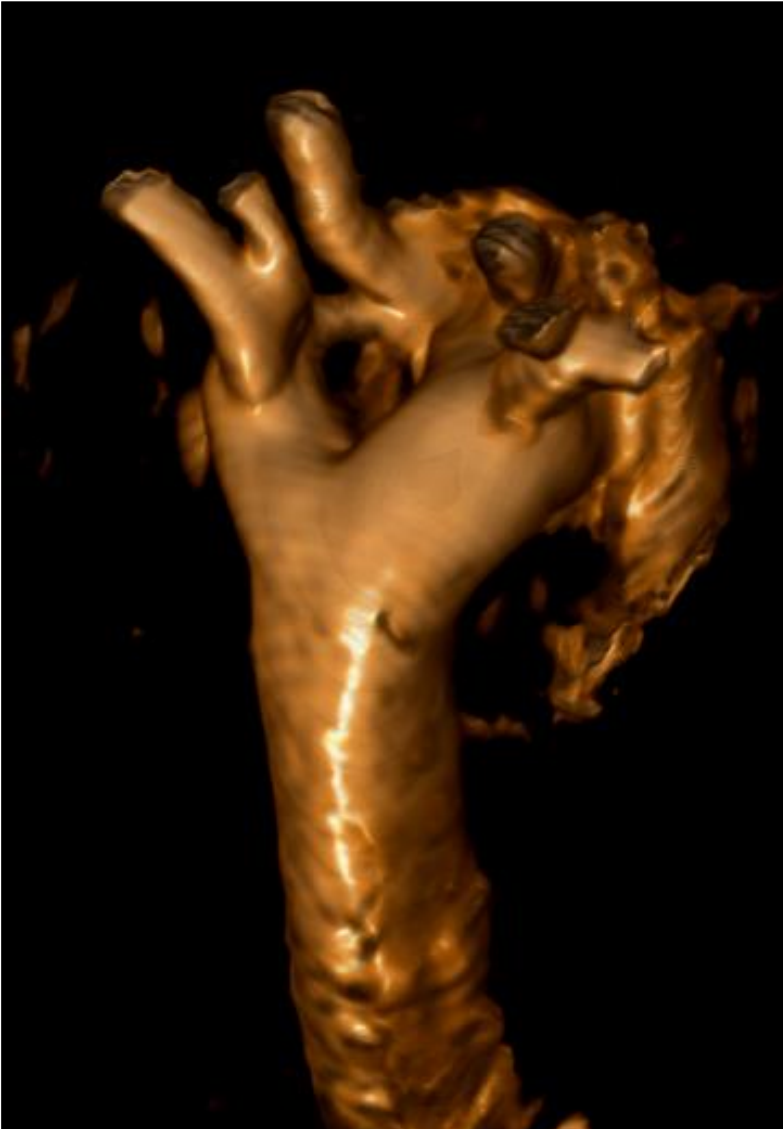SpatRes:0.000



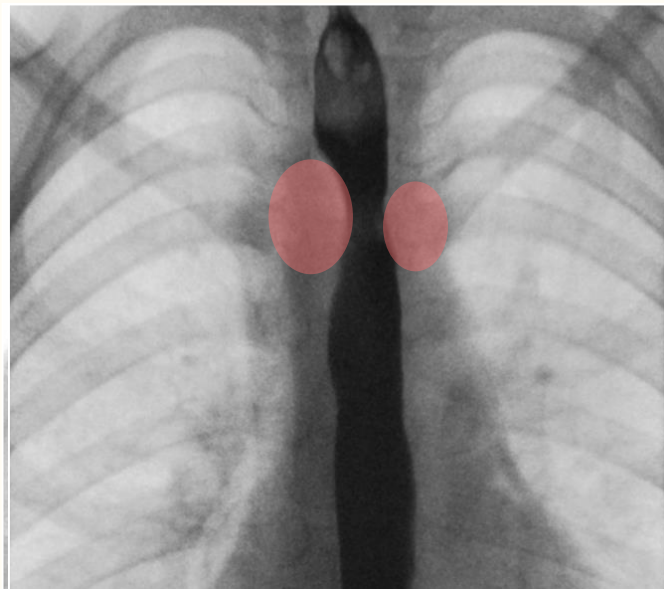
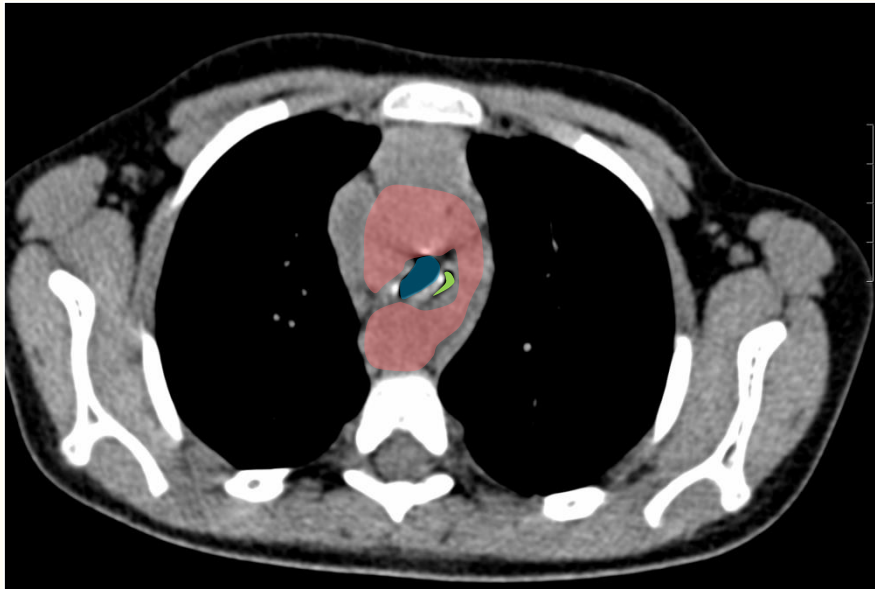
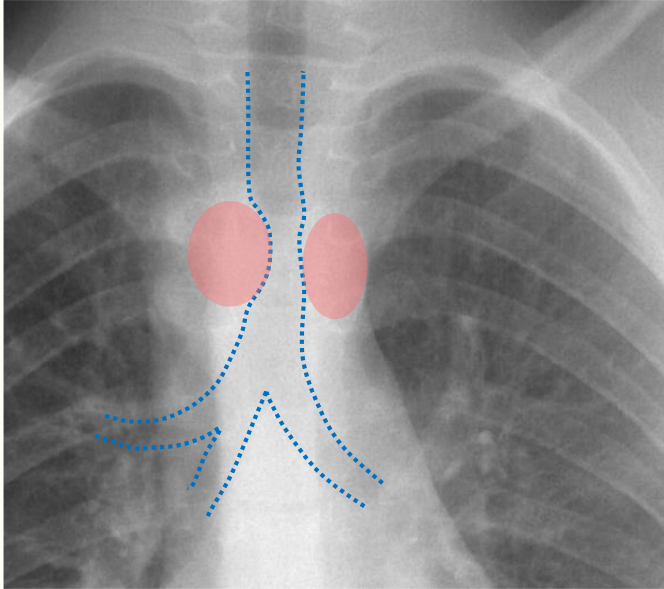
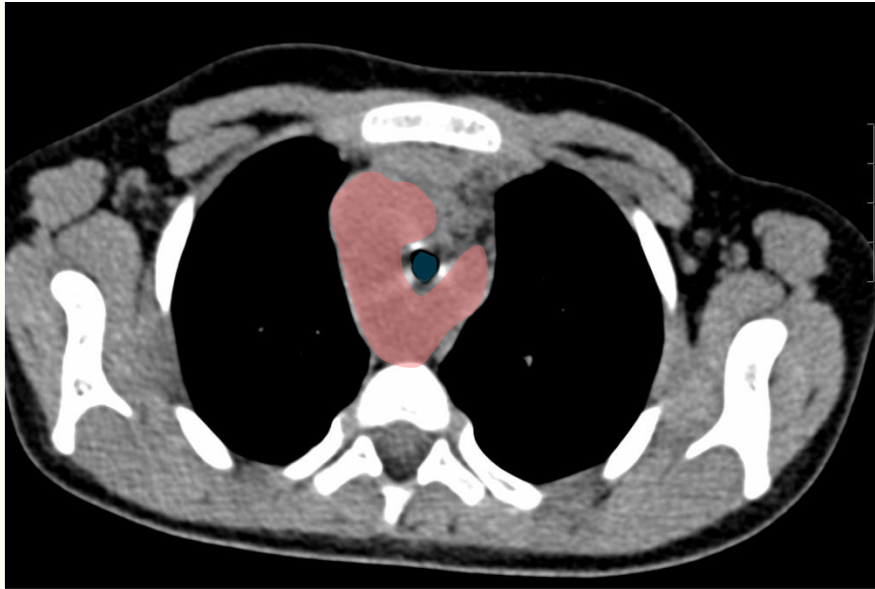



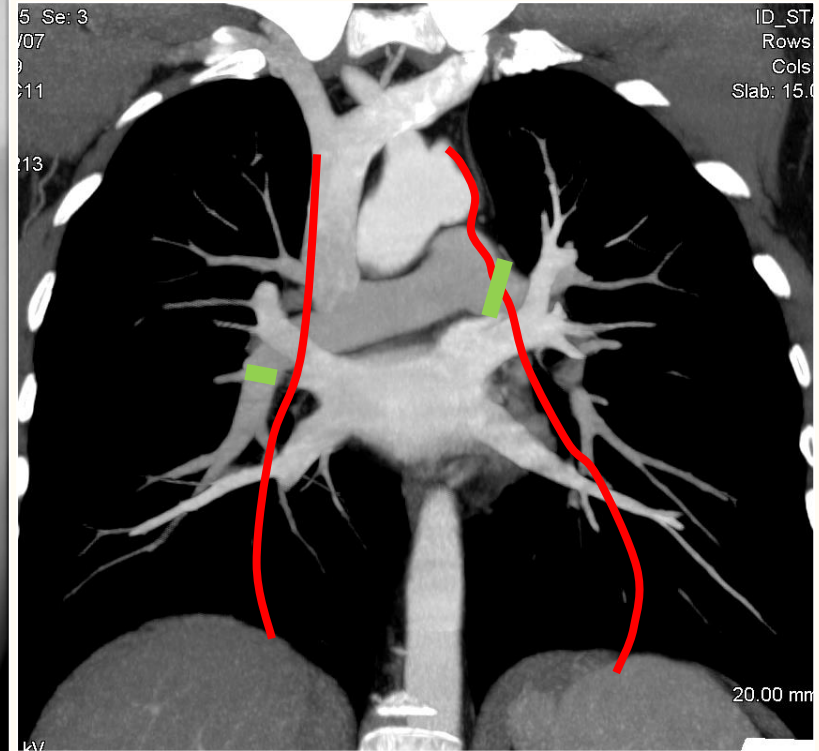
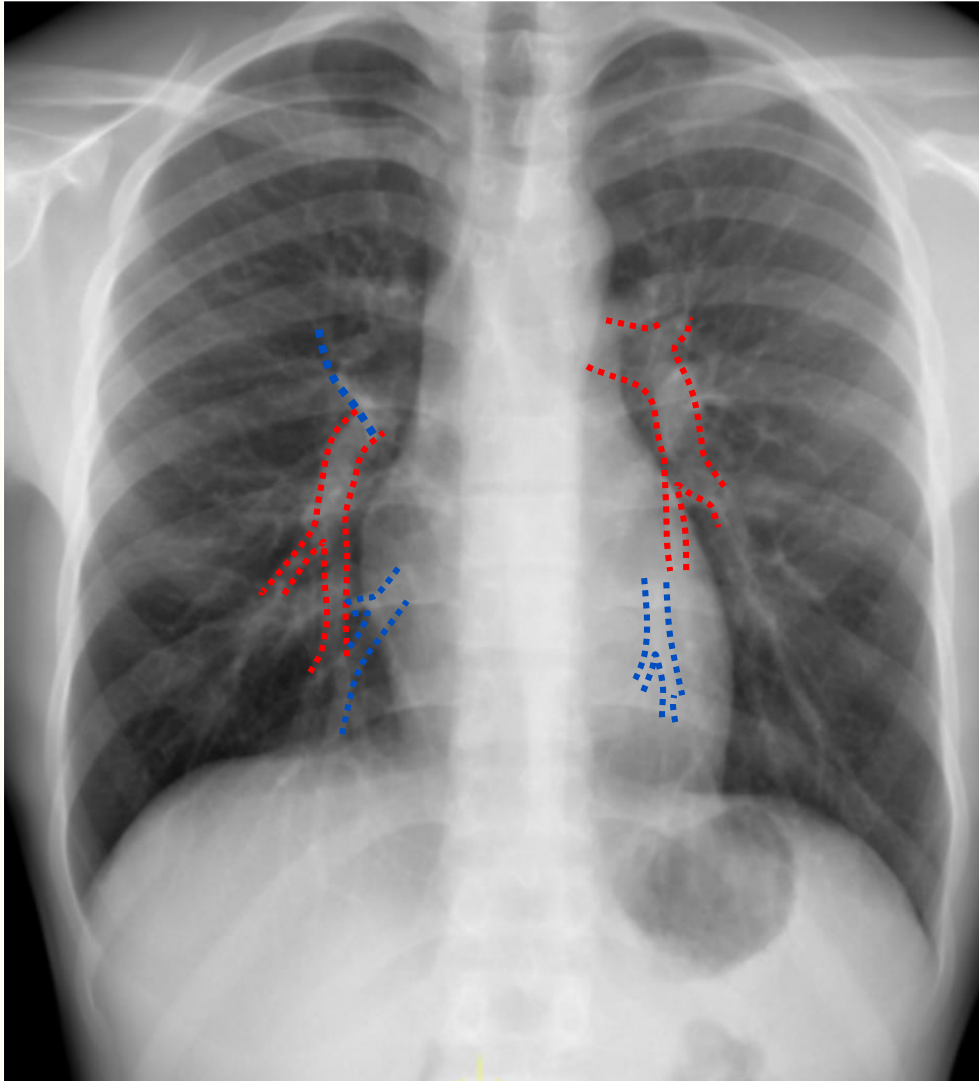




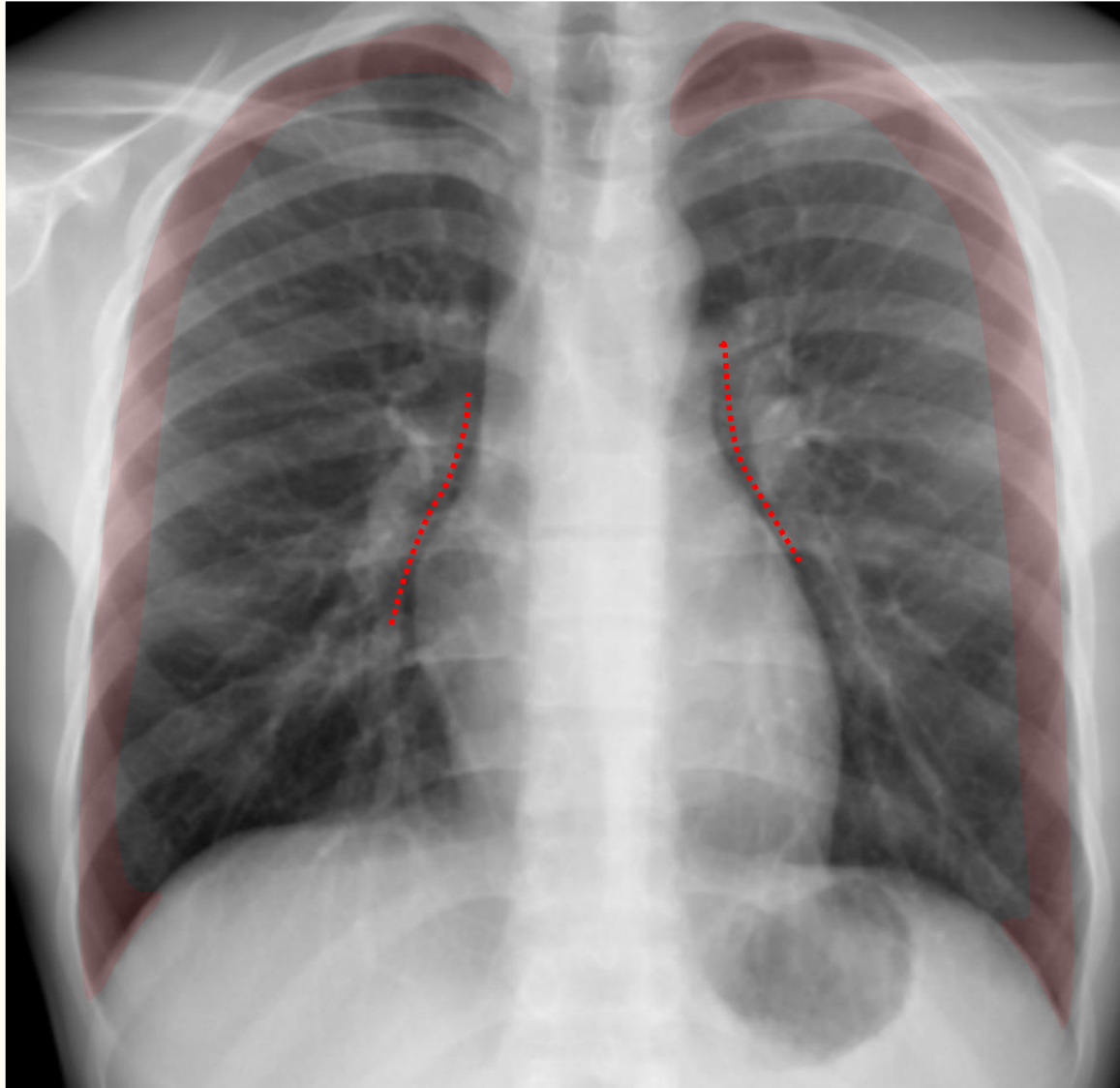
Çift Arkus Aorta – Komplet Vasküler Halka

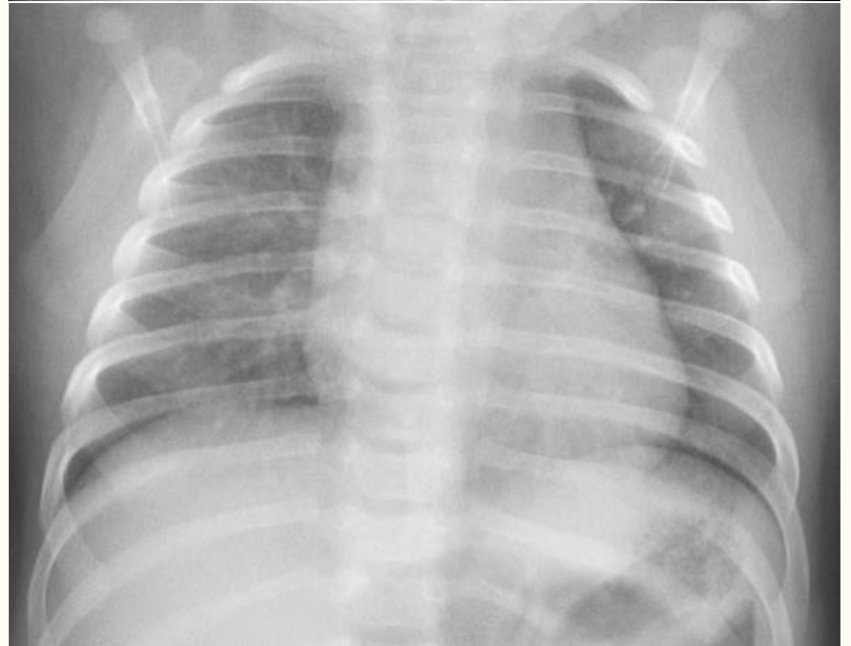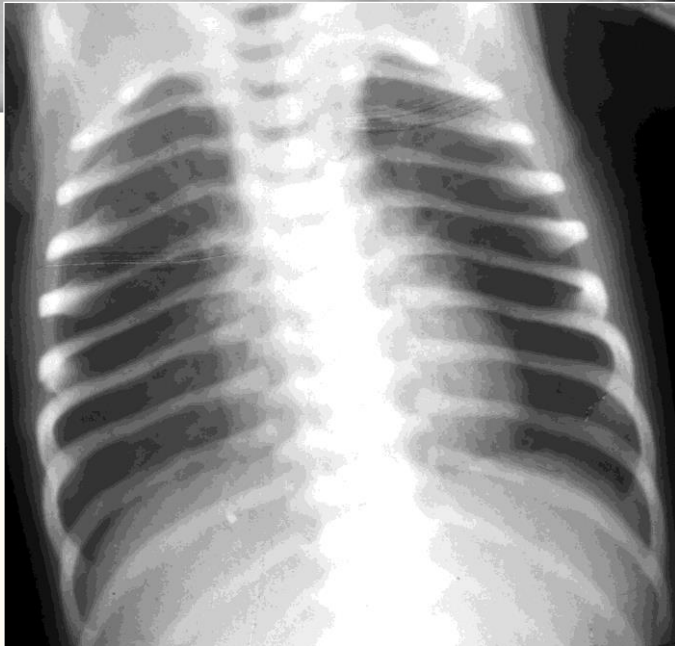
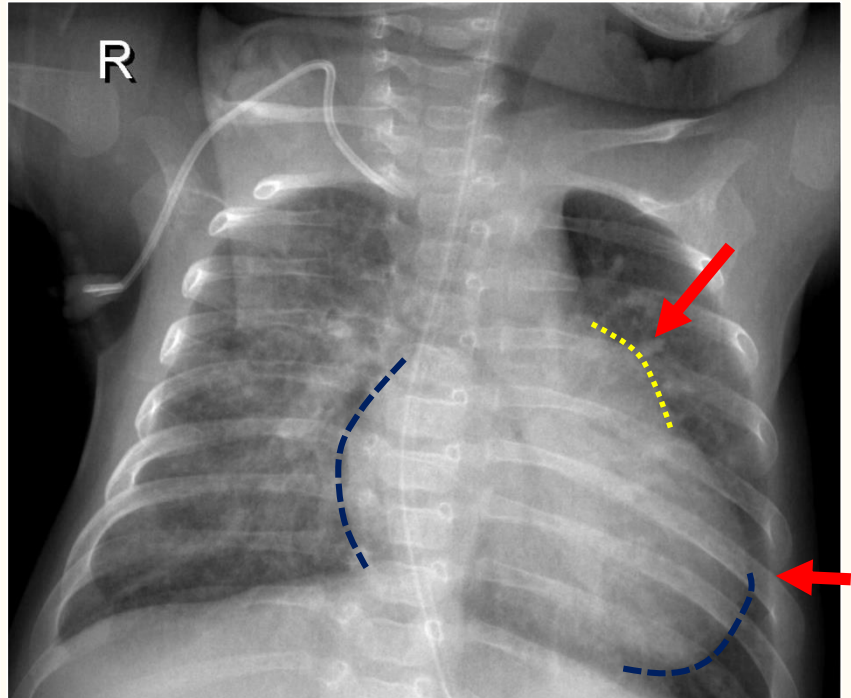
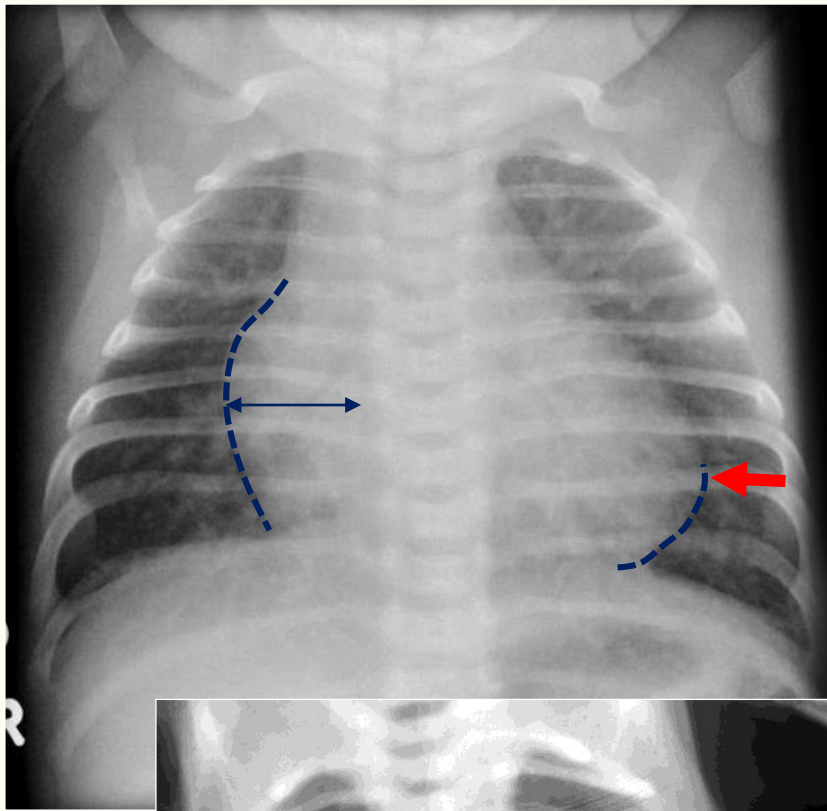


Akciğer Hilusları ve Vasküler Yapıları



«Parakiteğər Üldən Səpləsi»



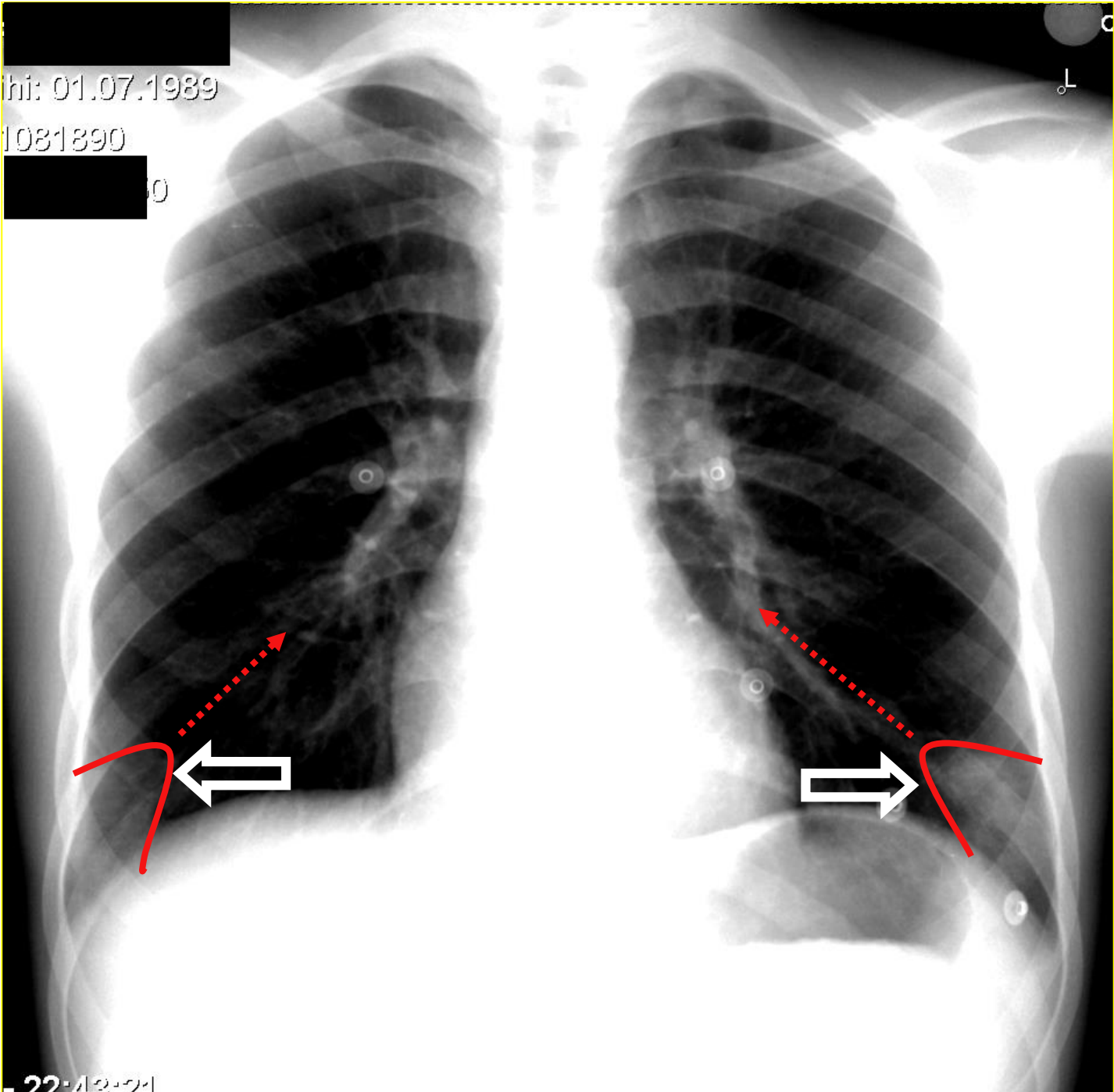


dat: 01.07.1989

1081890

0

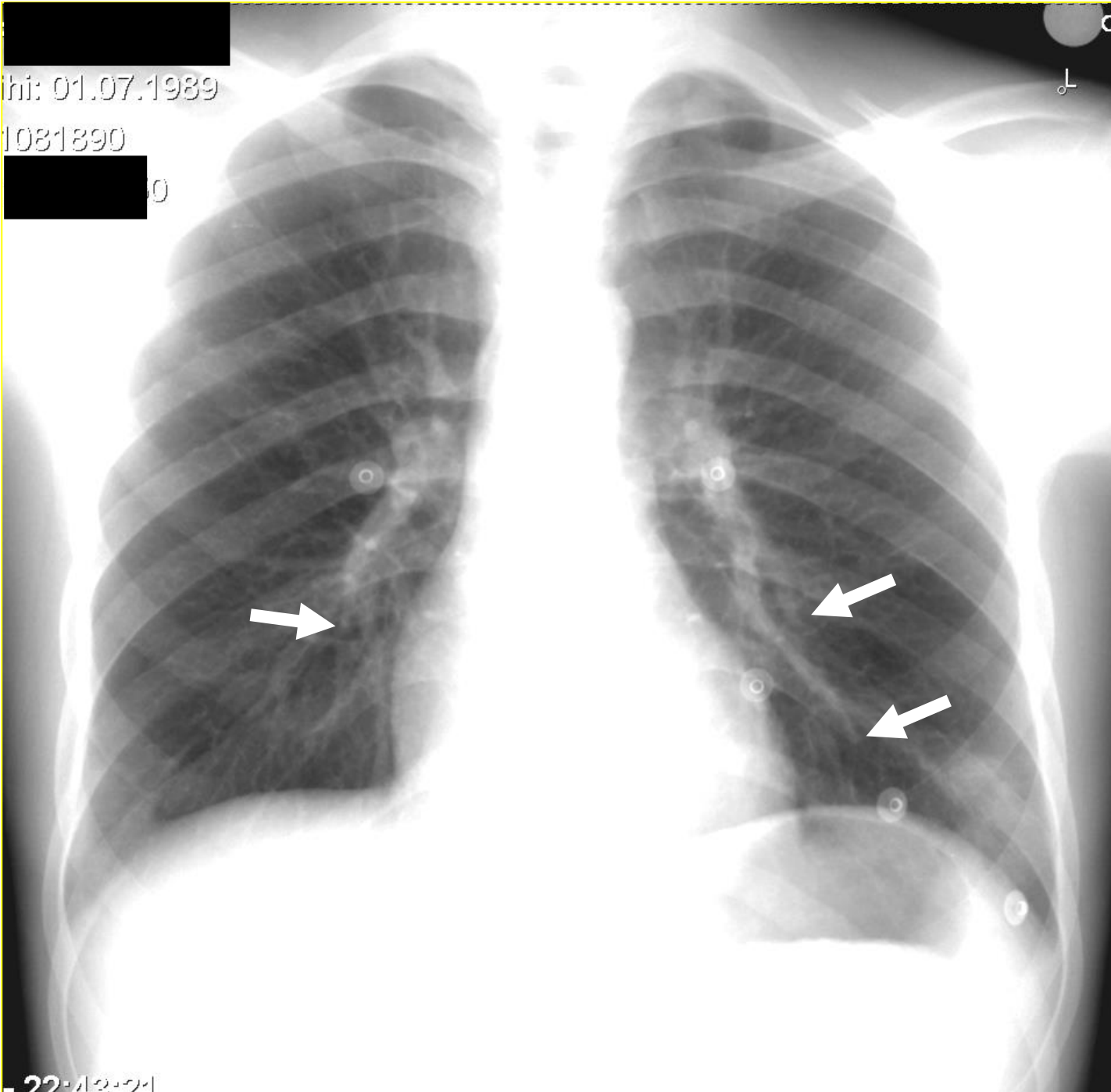
22.12.21



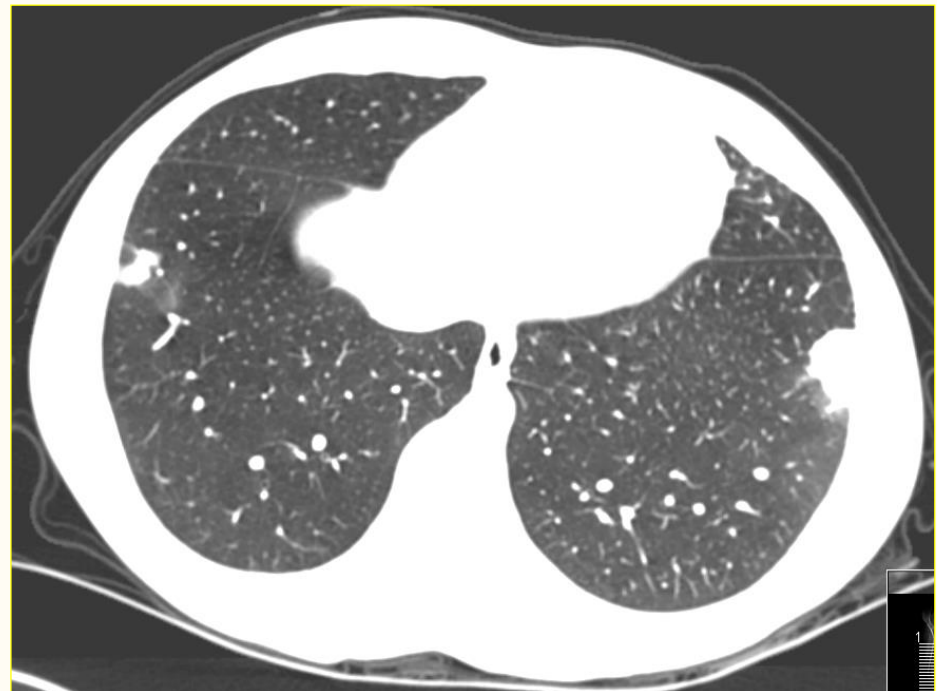
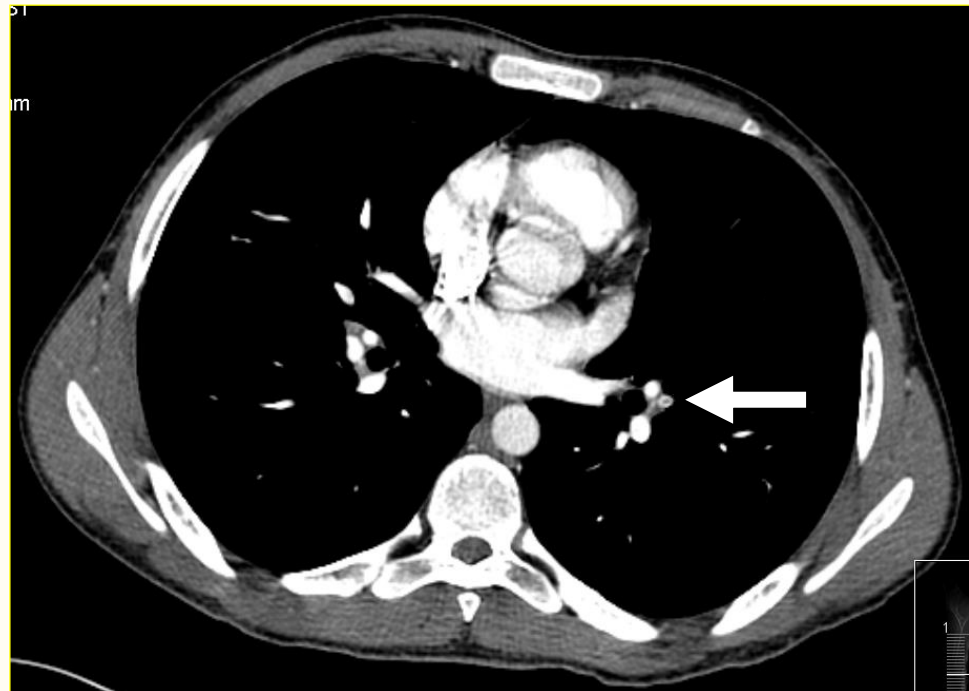
hi: 01.07.1989

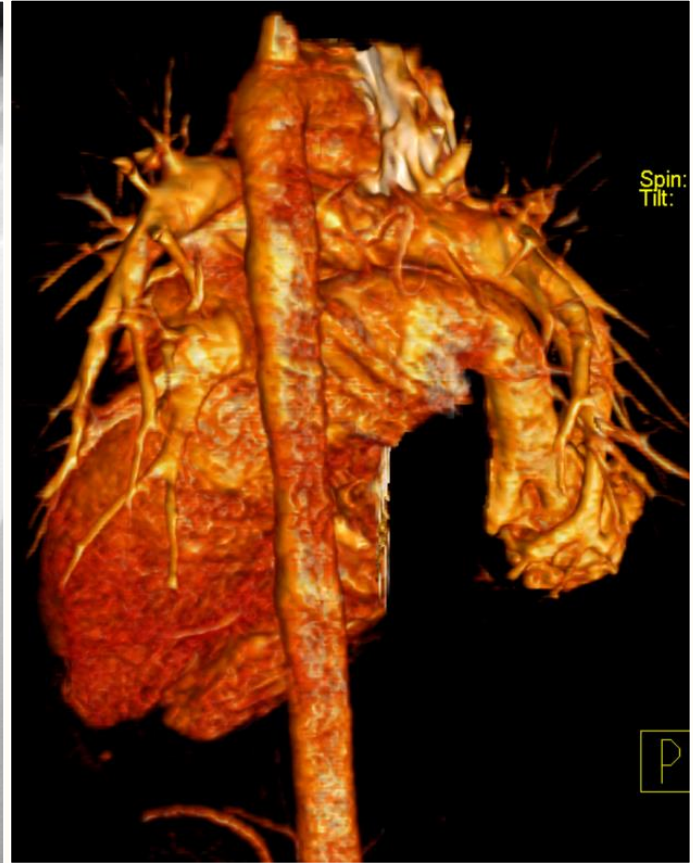
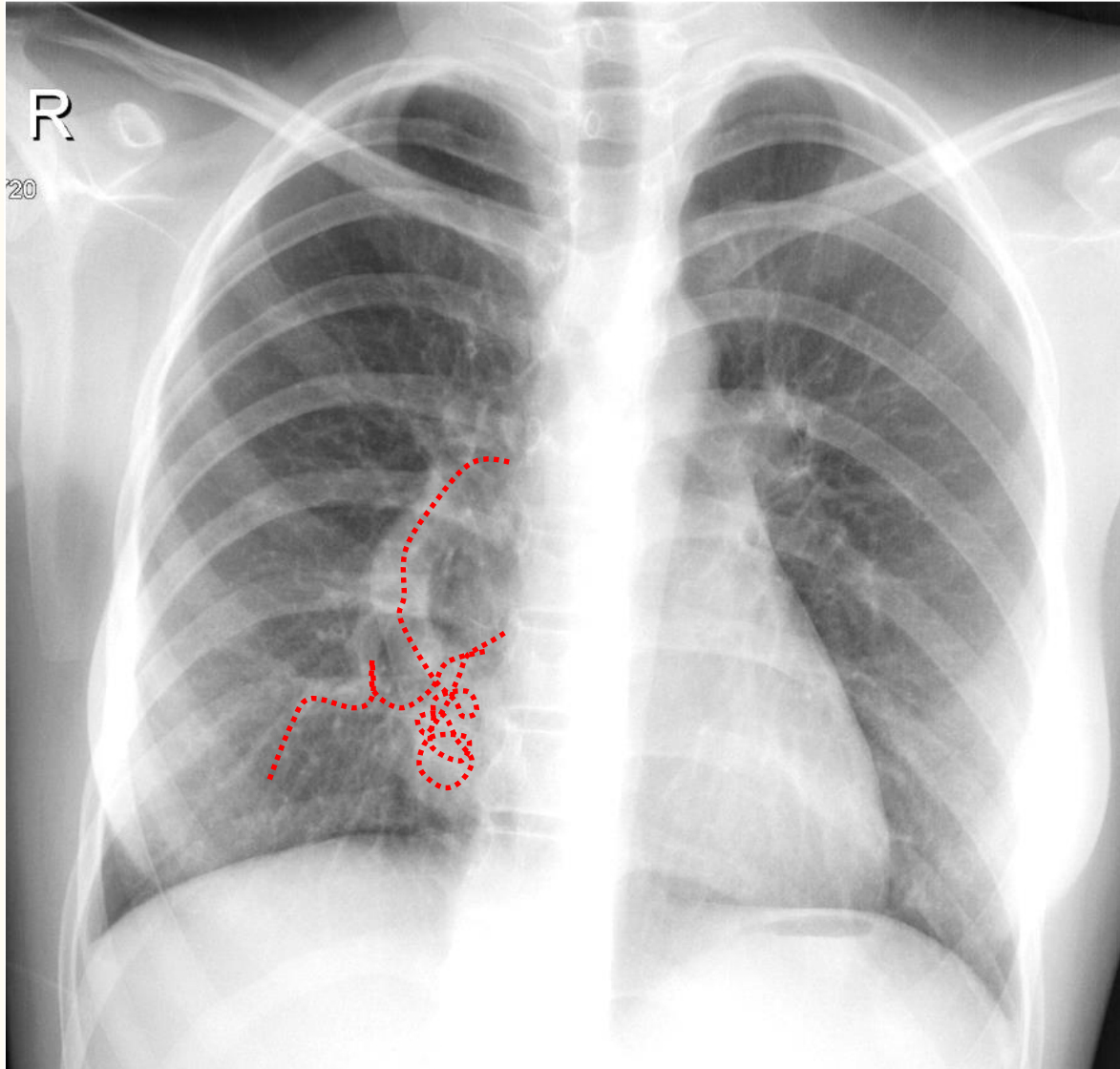
1081890

0



22.12.2021





Radyografik Dansiteler

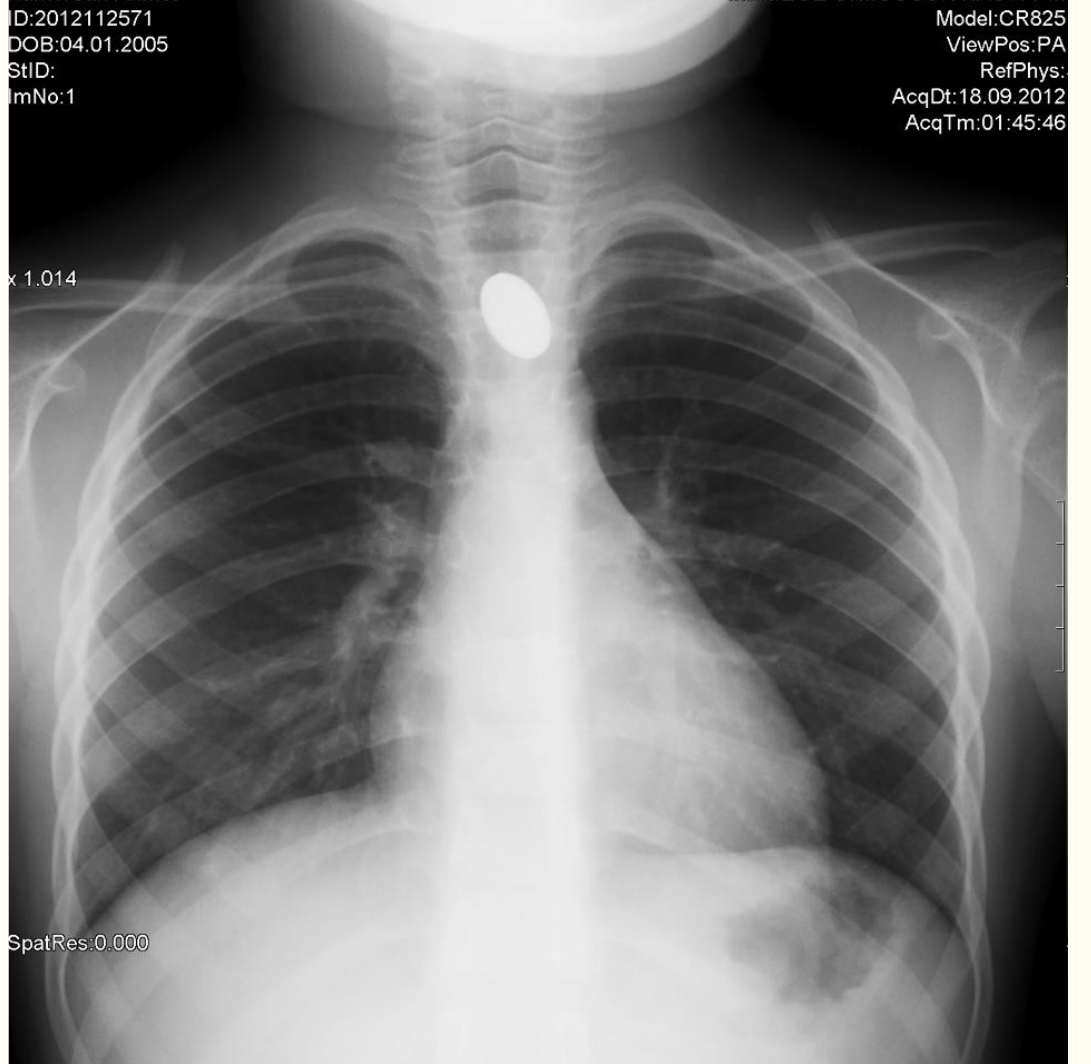Metalik dansite

Kalsiyum dansitesi

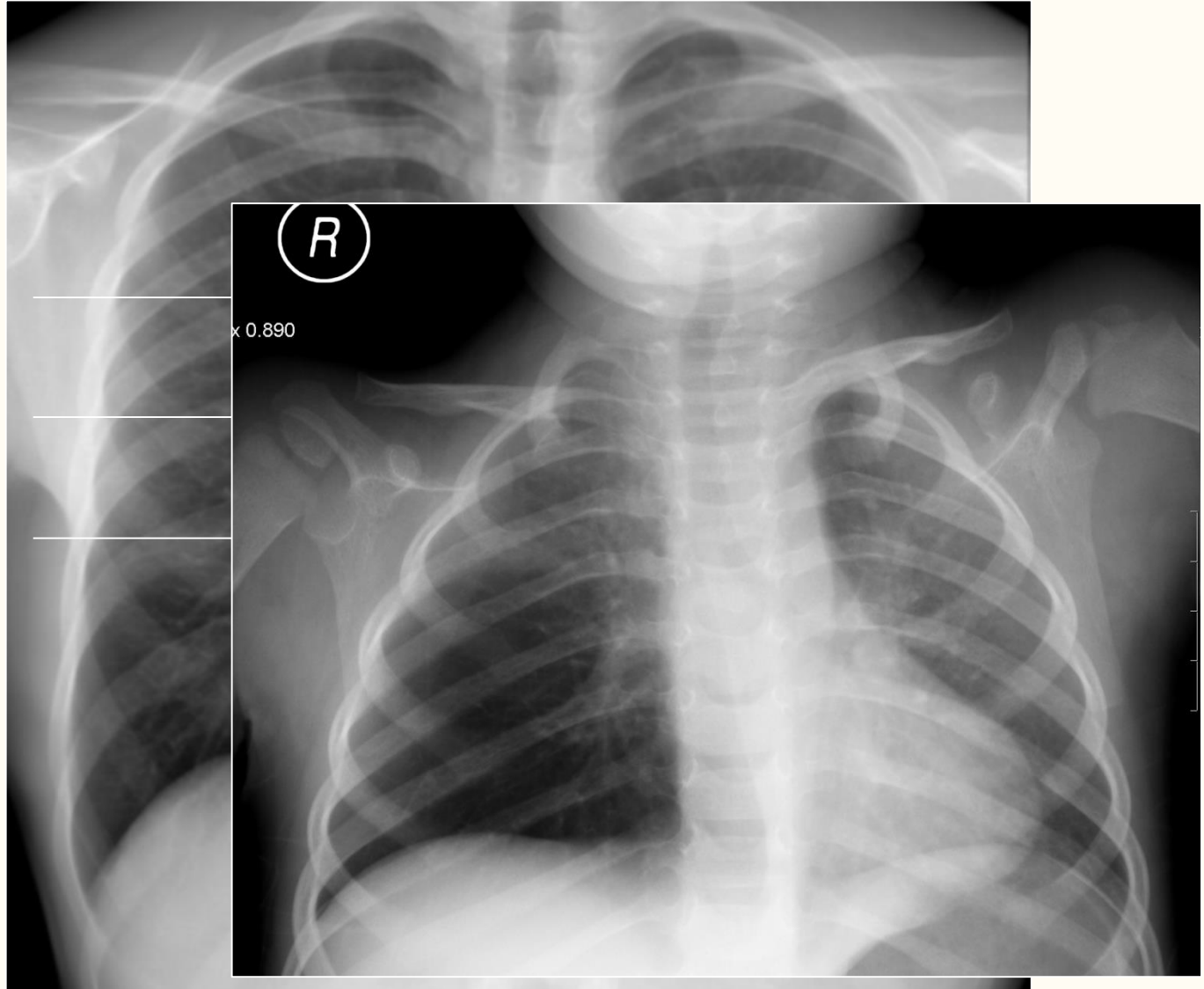
Su dansitesi

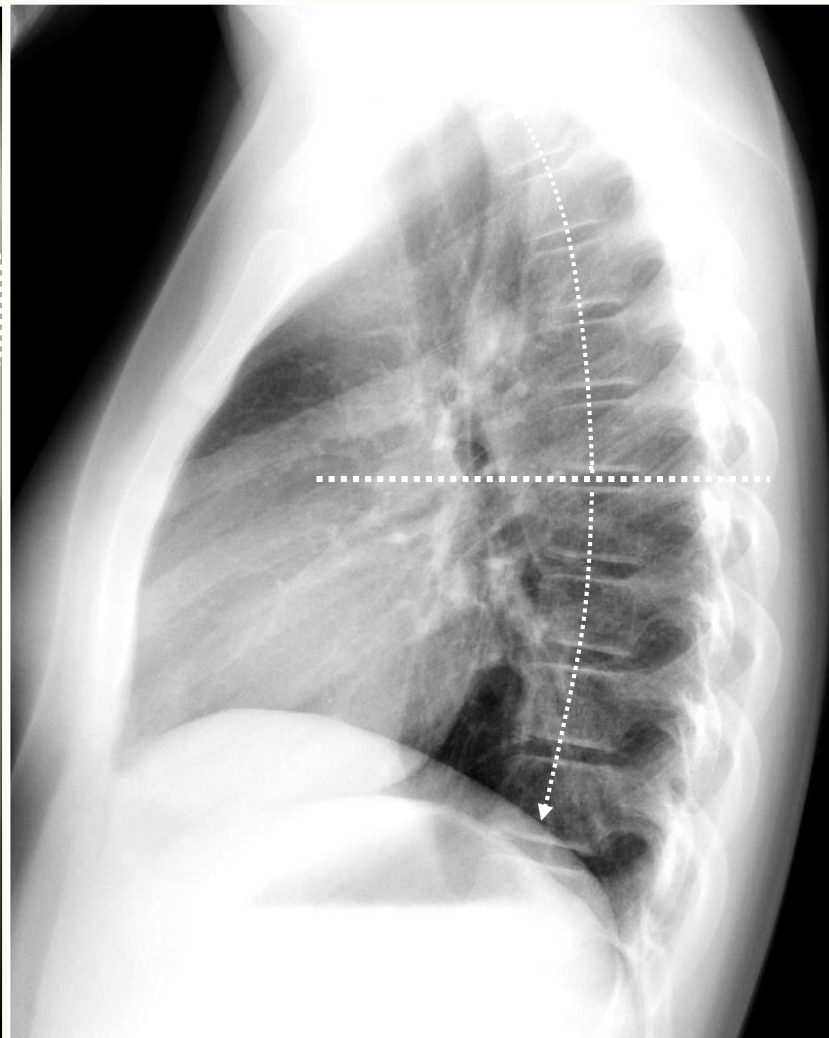
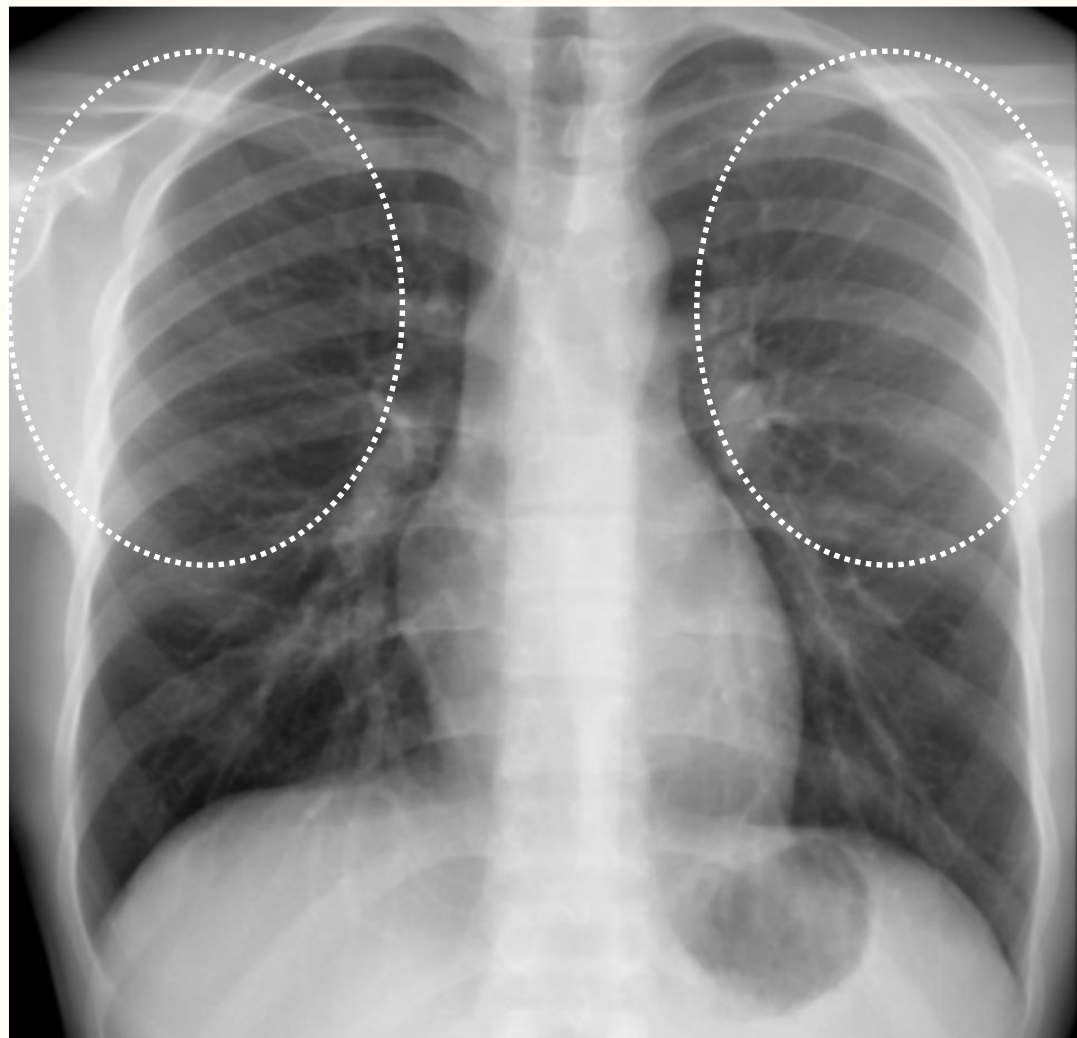
Yağ dansitesi

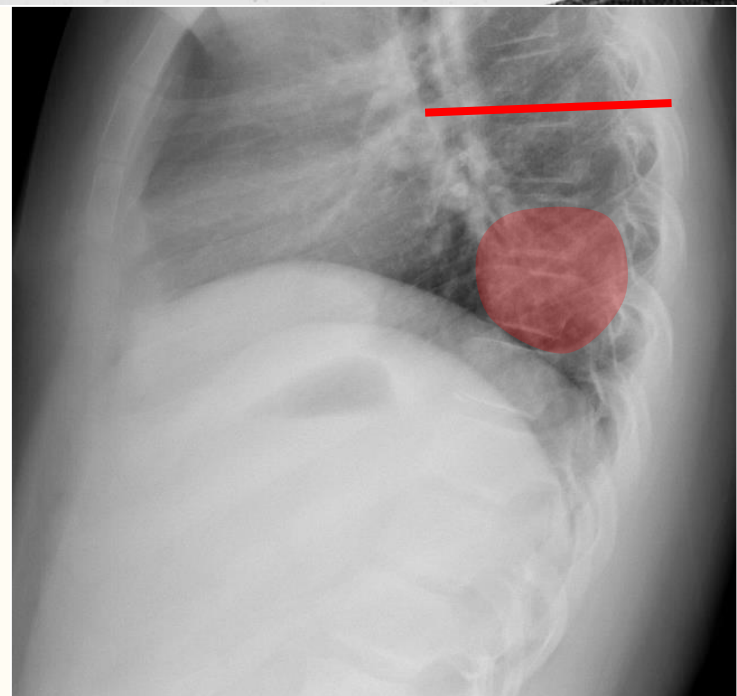
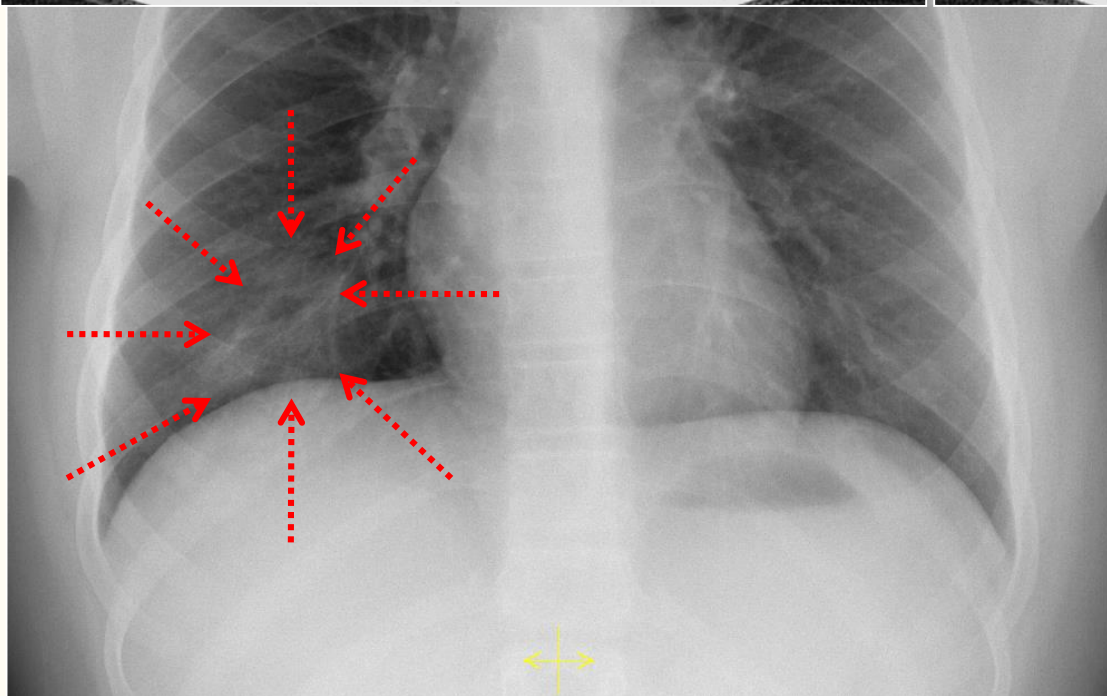
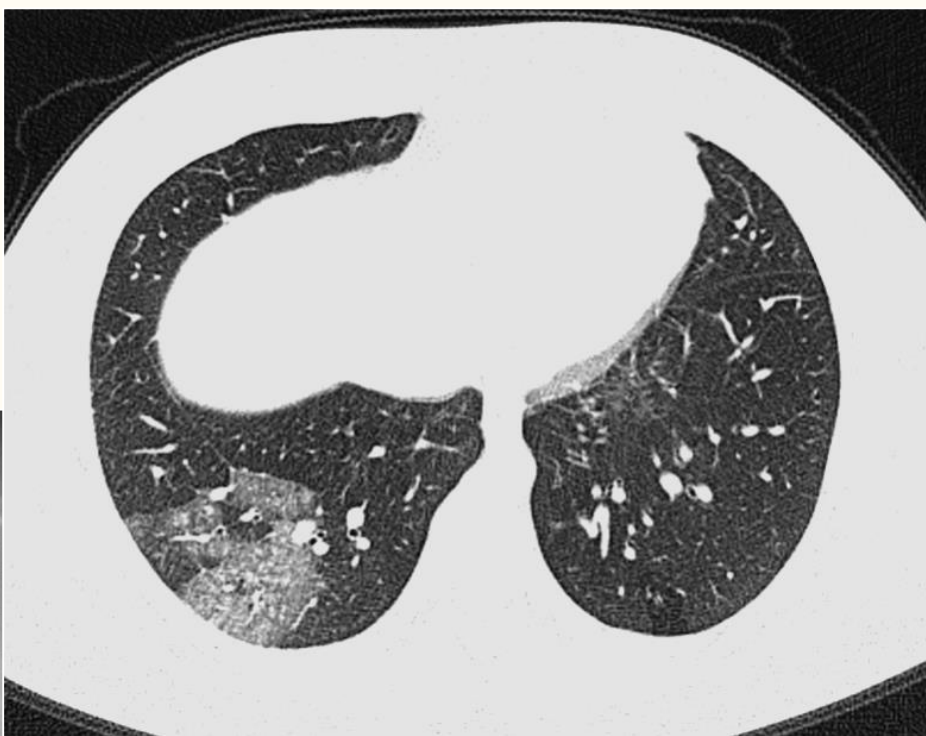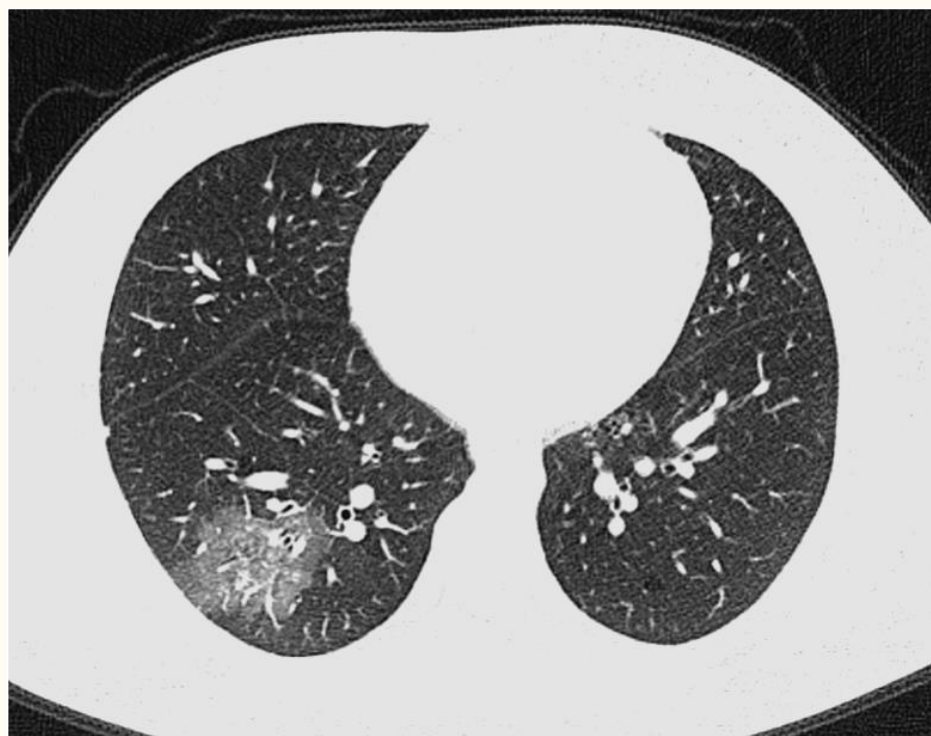Hava Dansitesi

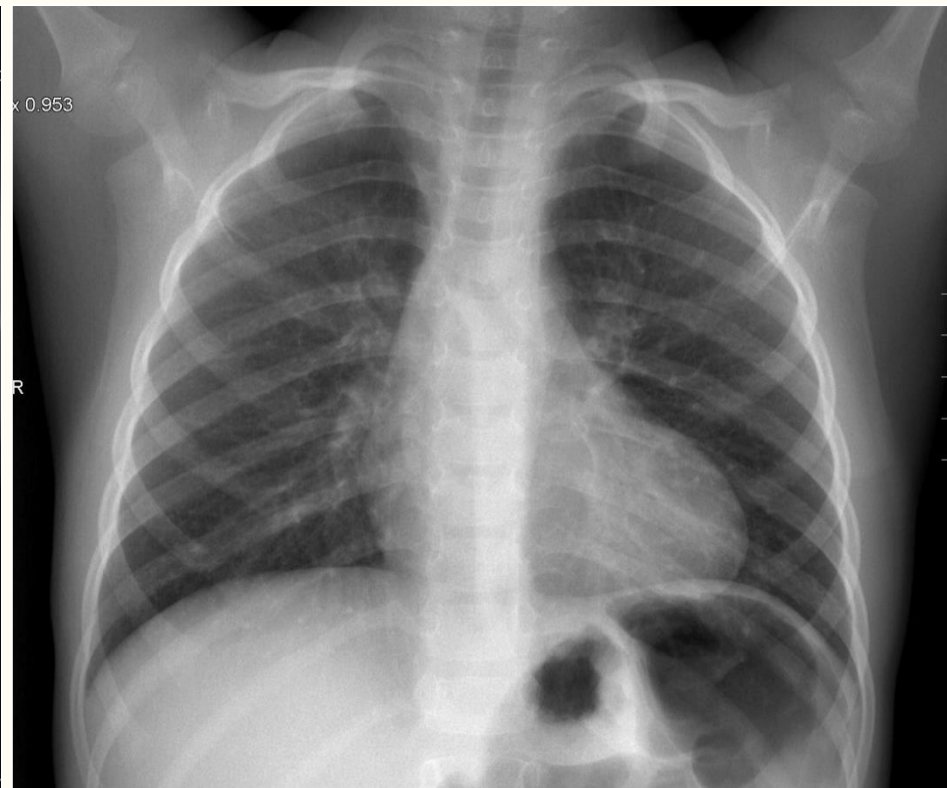
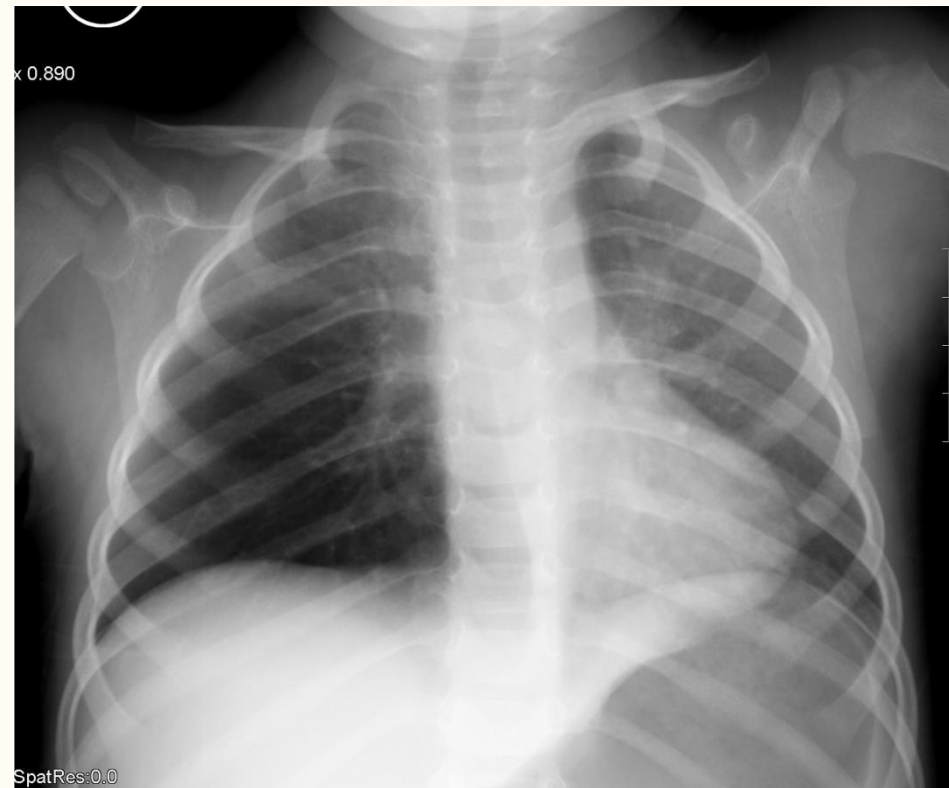


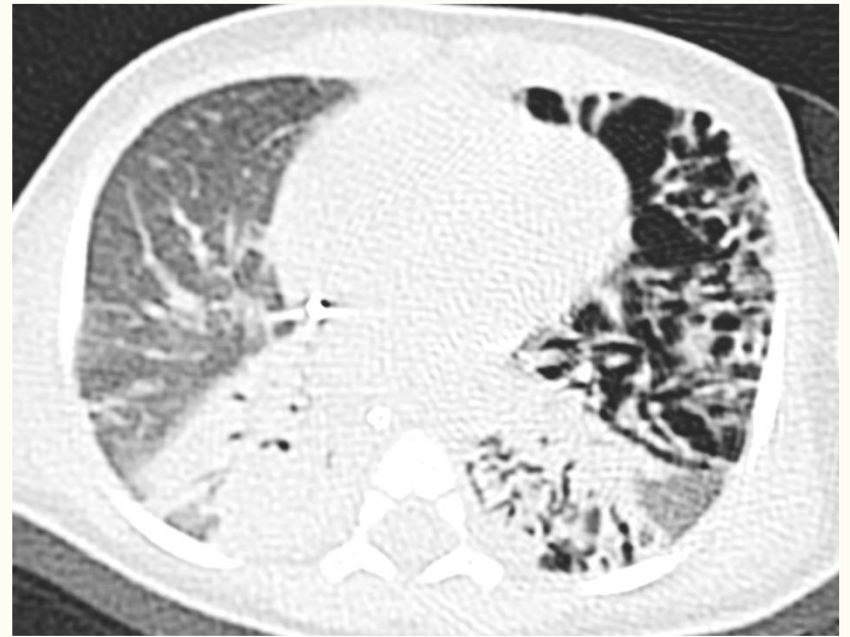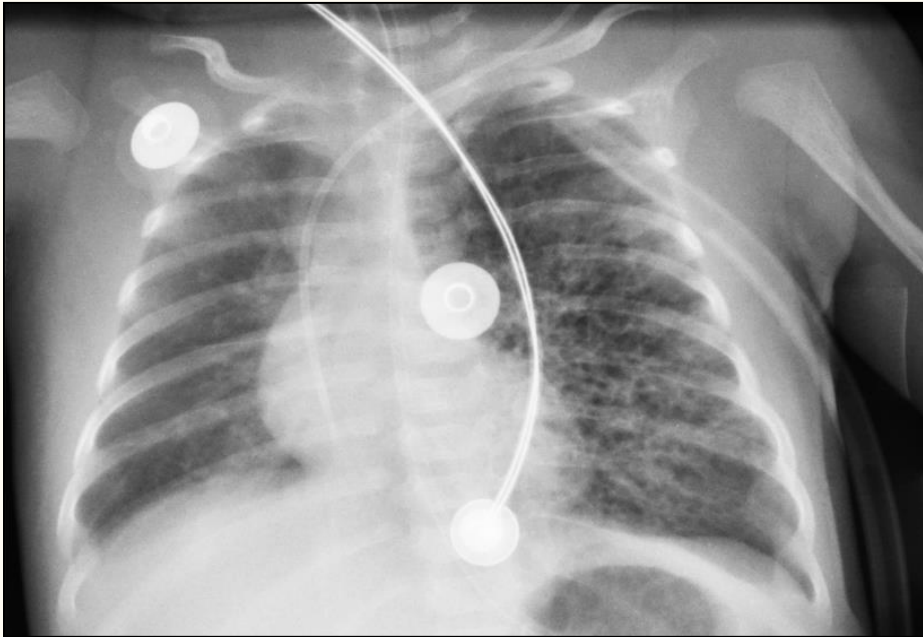
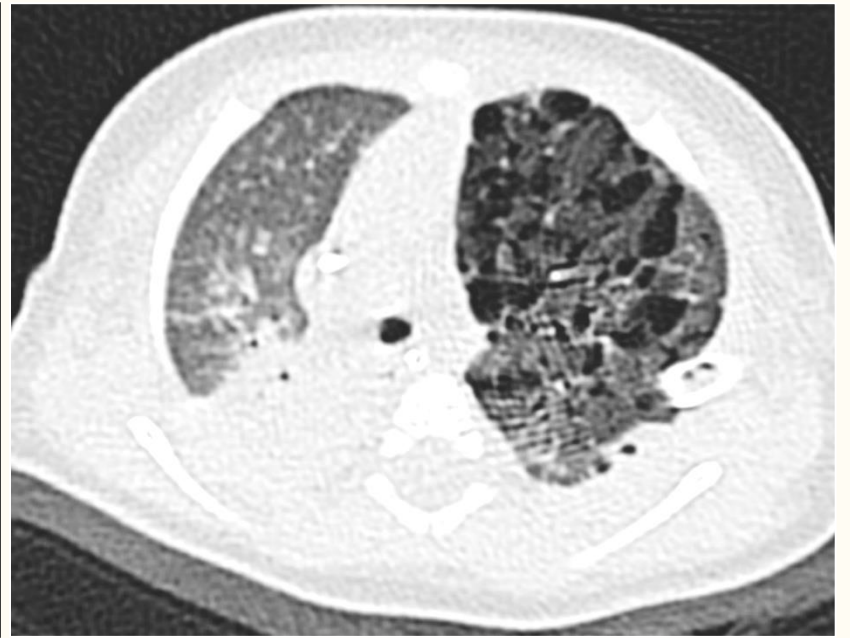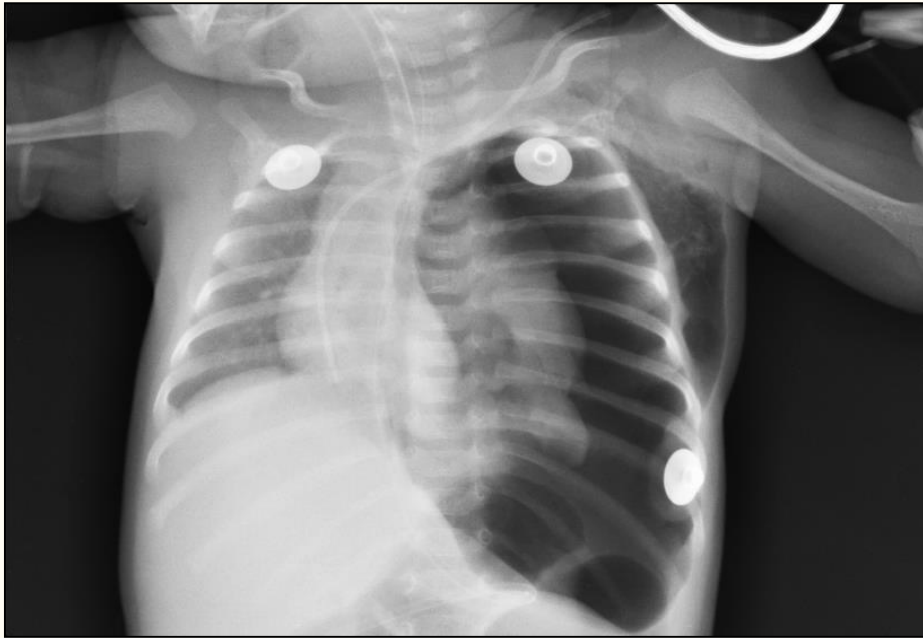
Akciğerin Radyografik Dansitesi

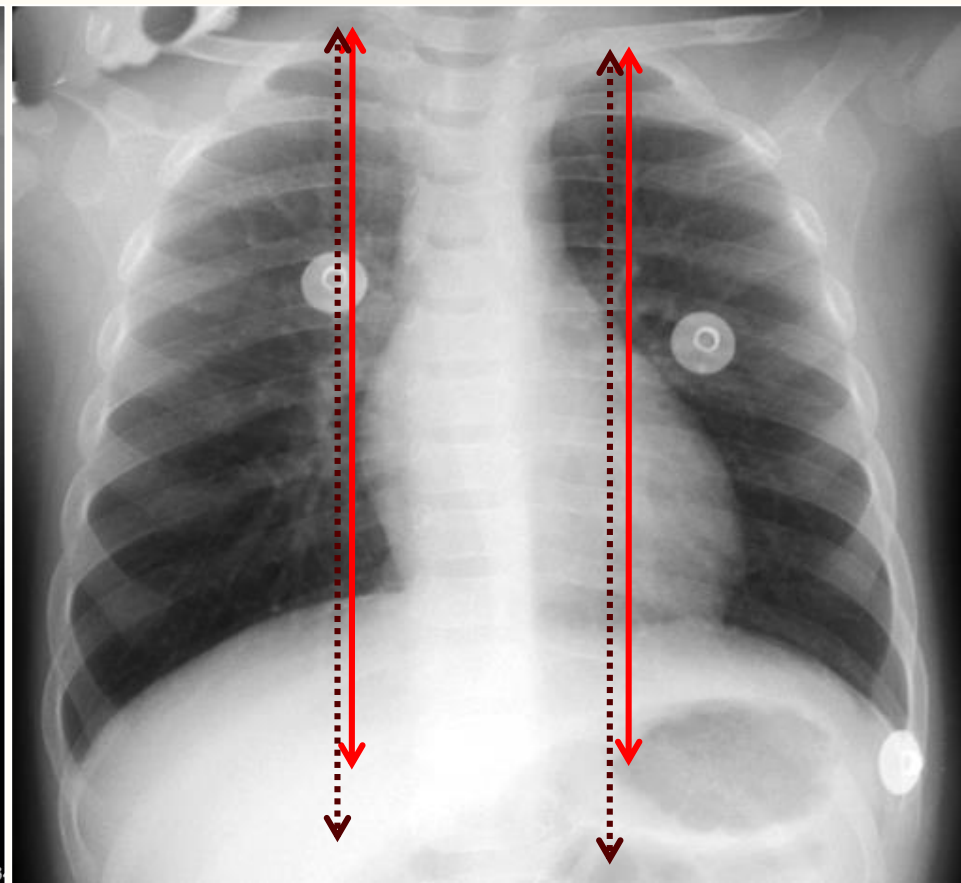
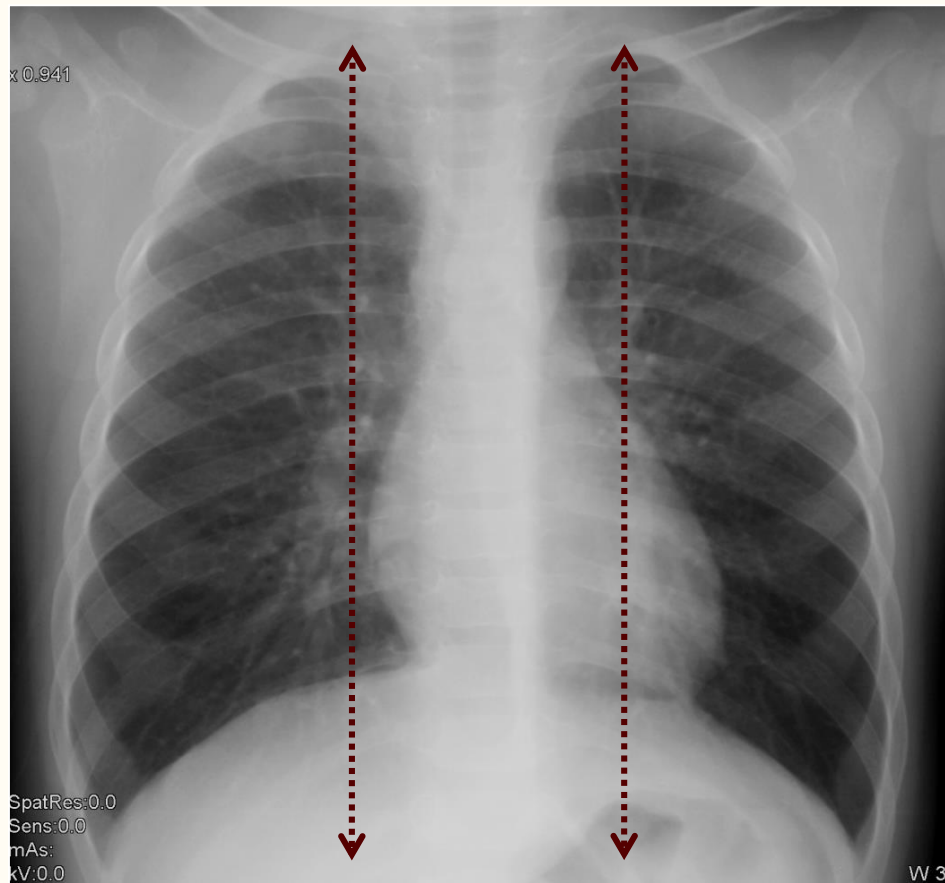


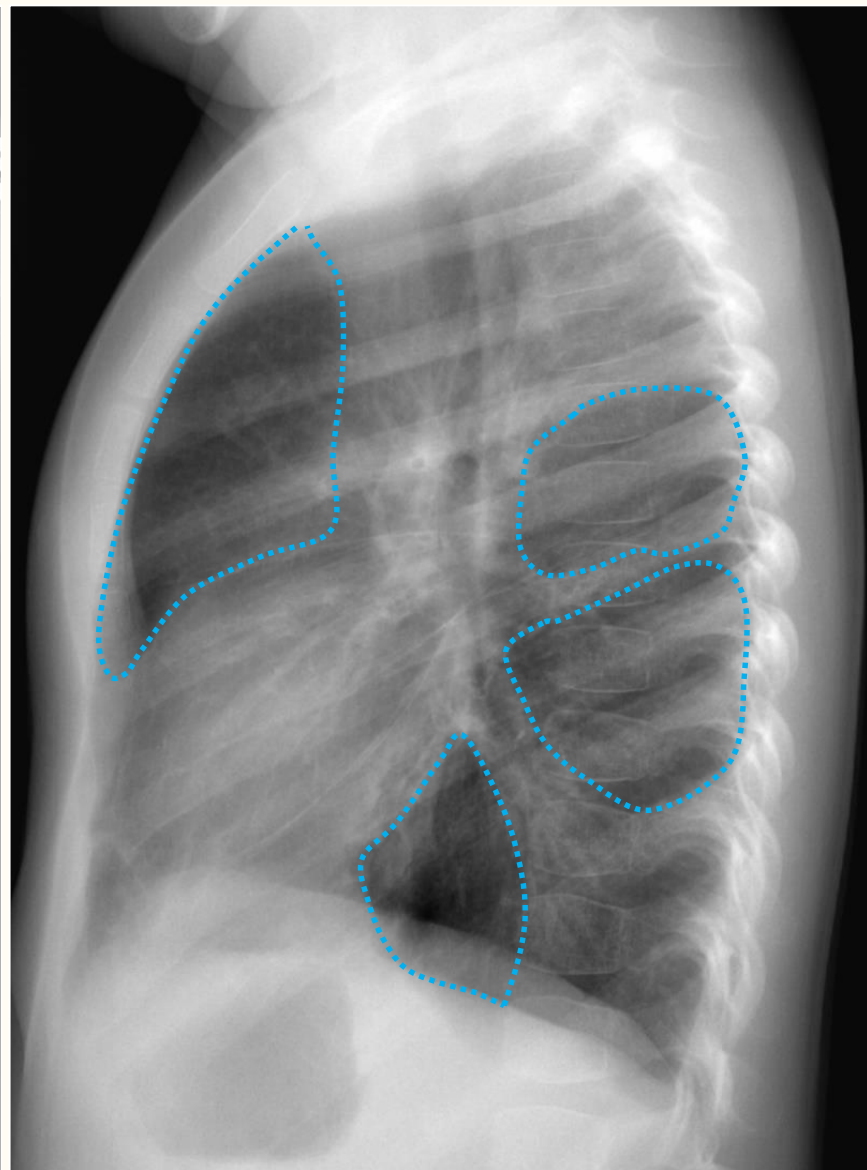
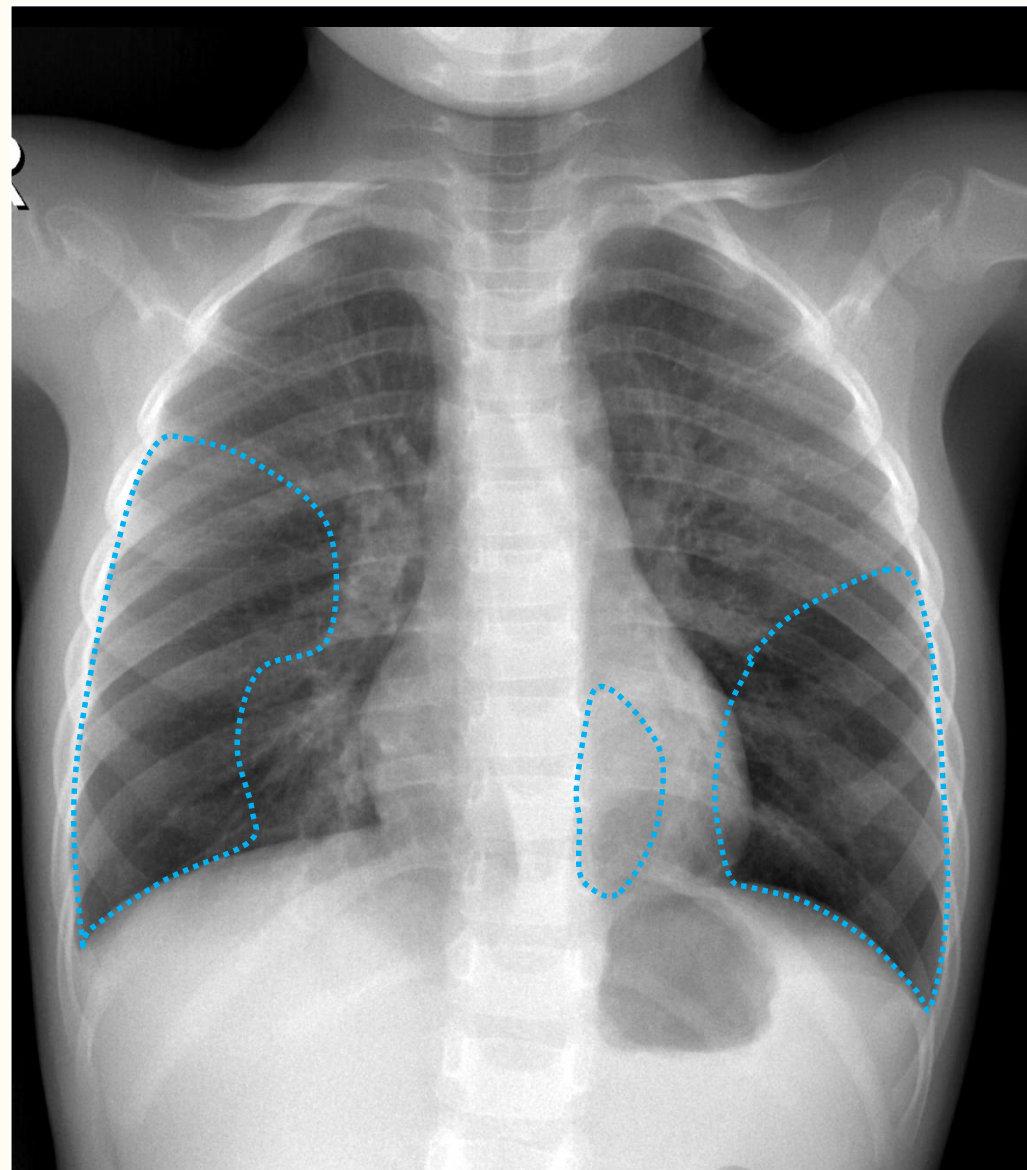


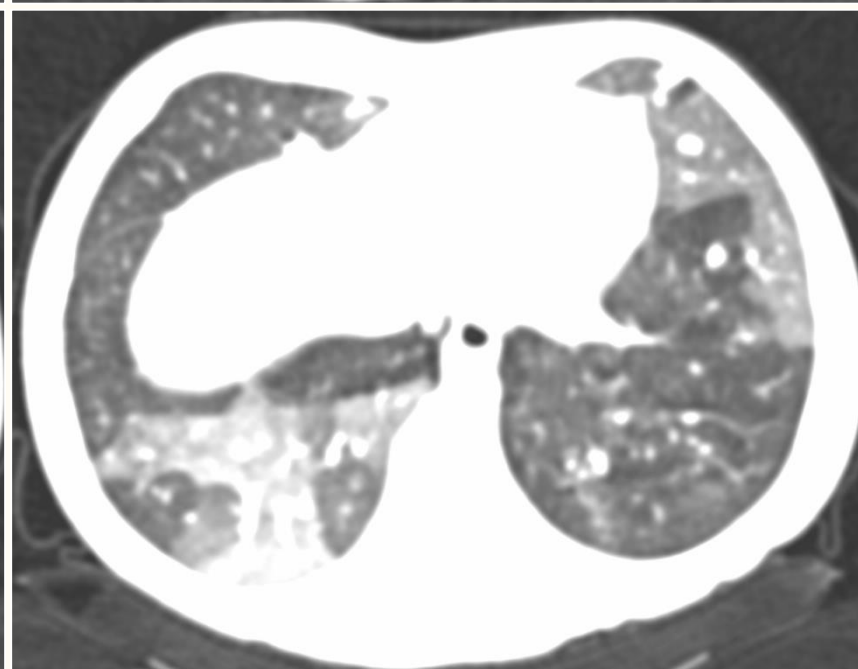
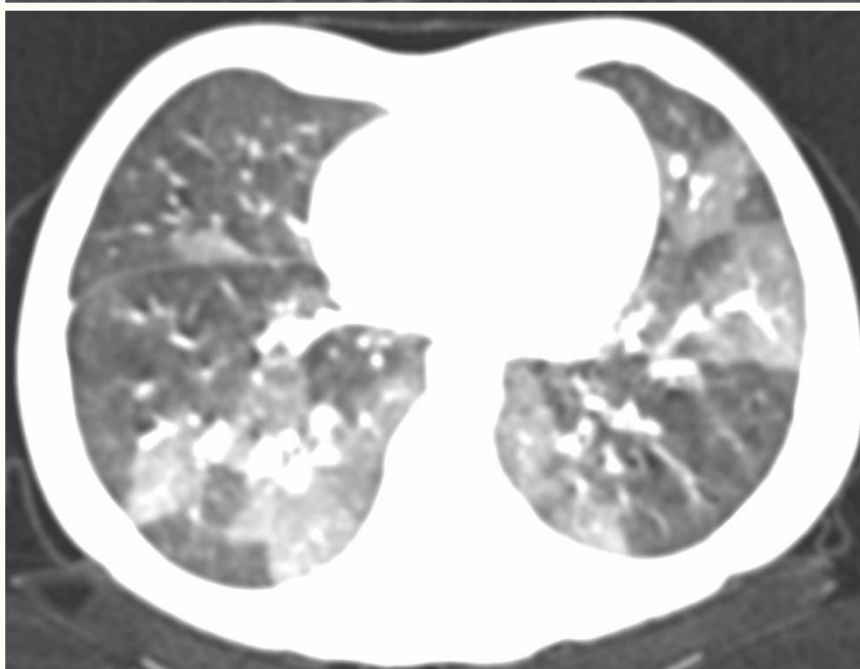
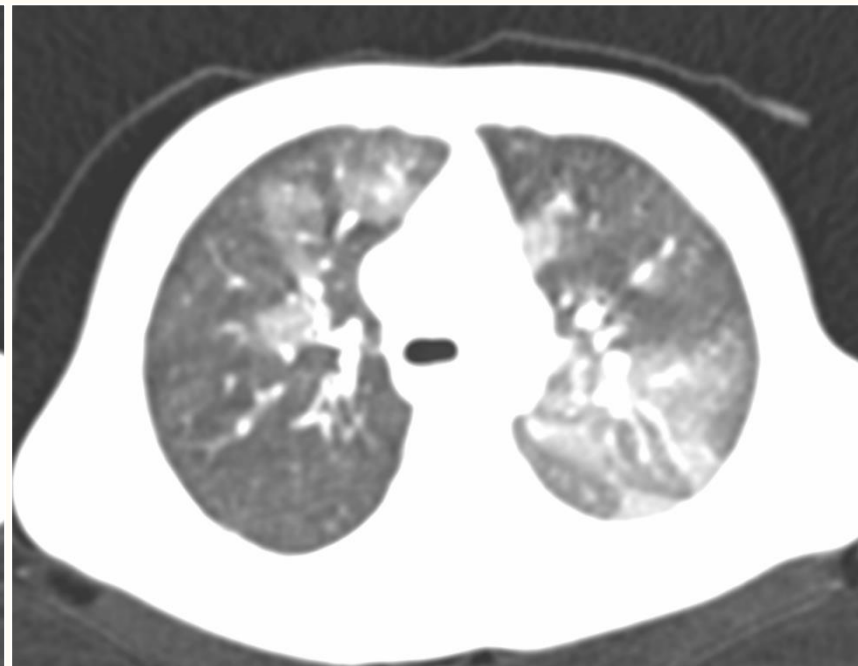
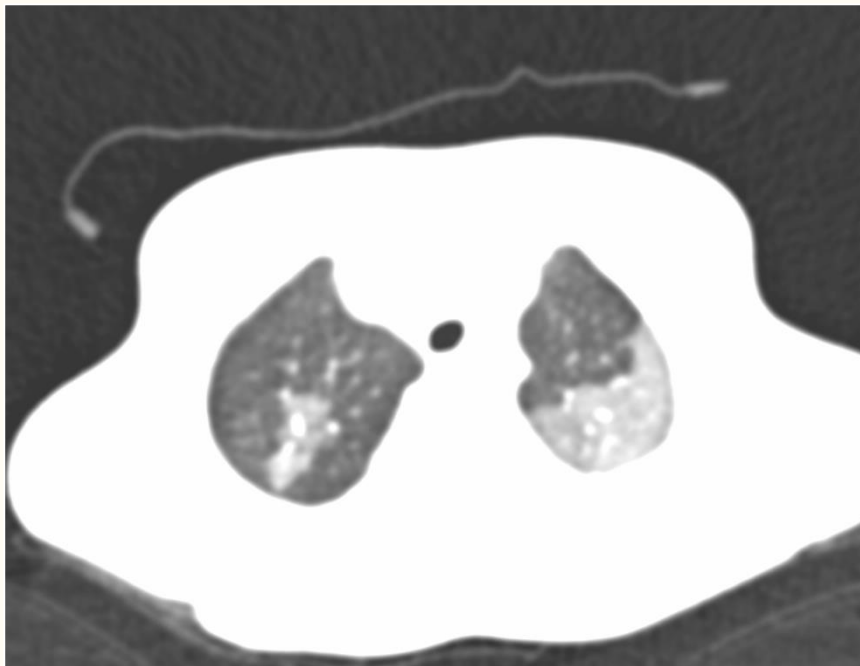








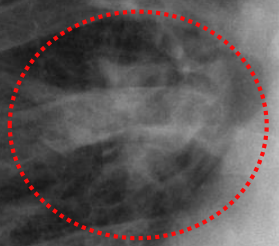




Amur Ali
002603
12.1998

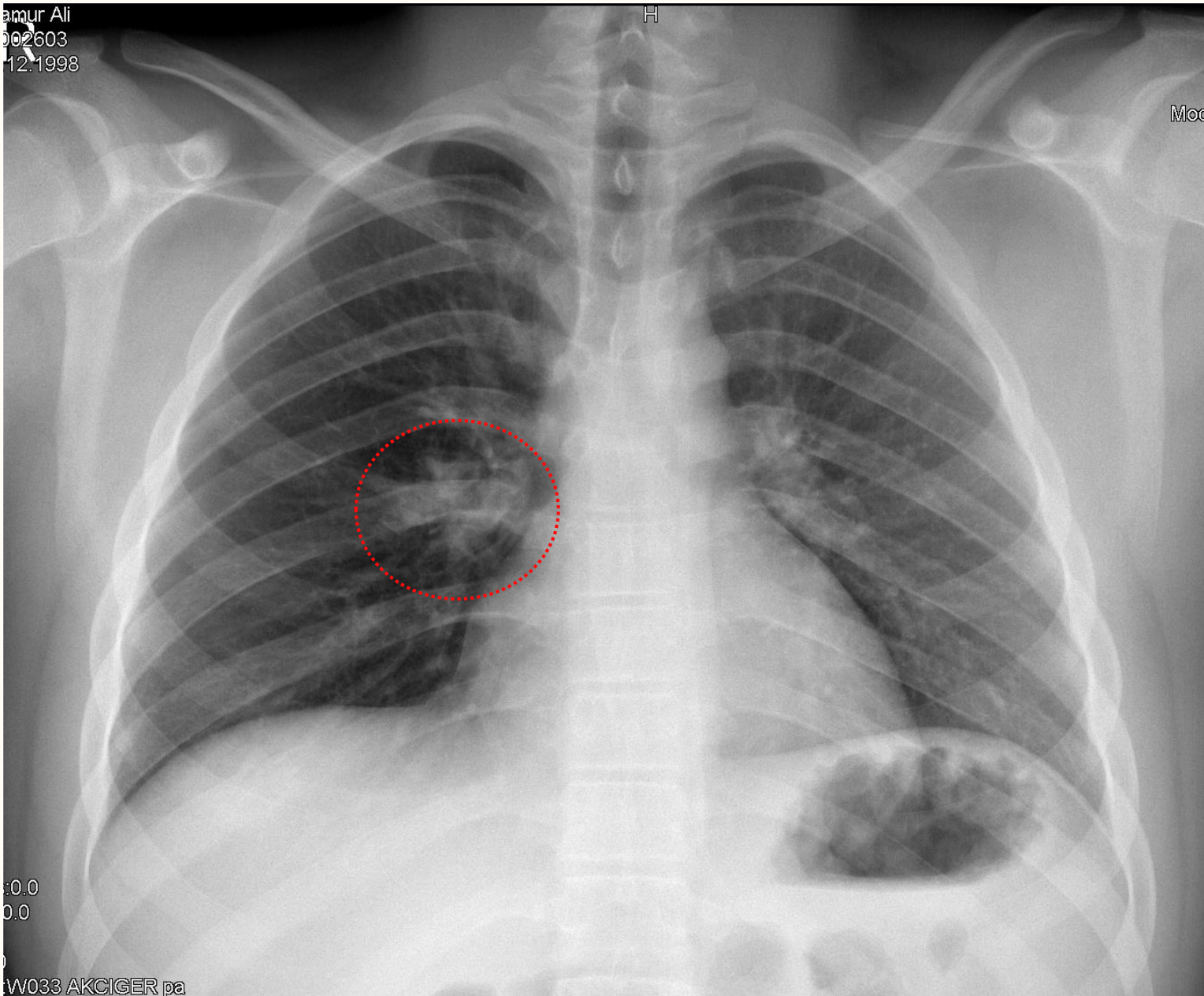
H

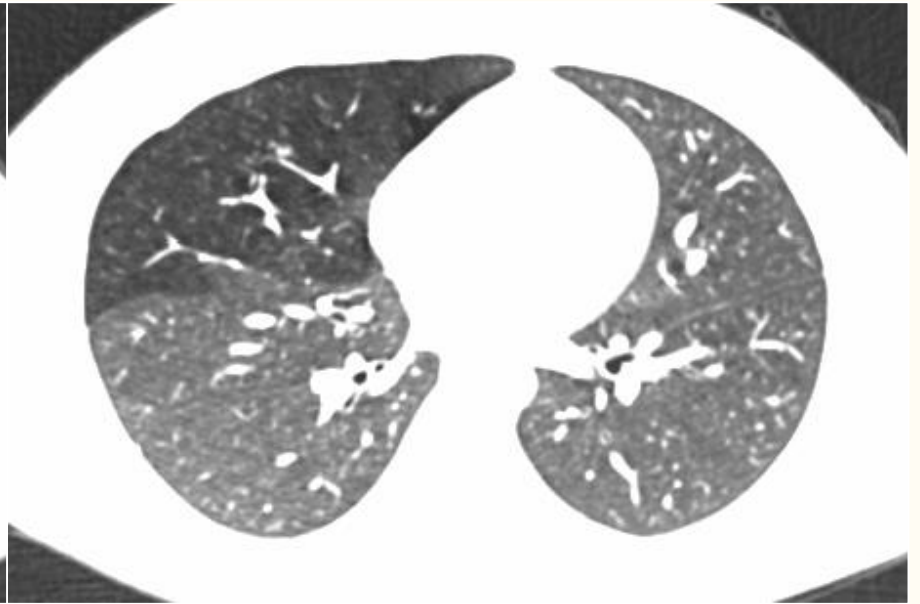
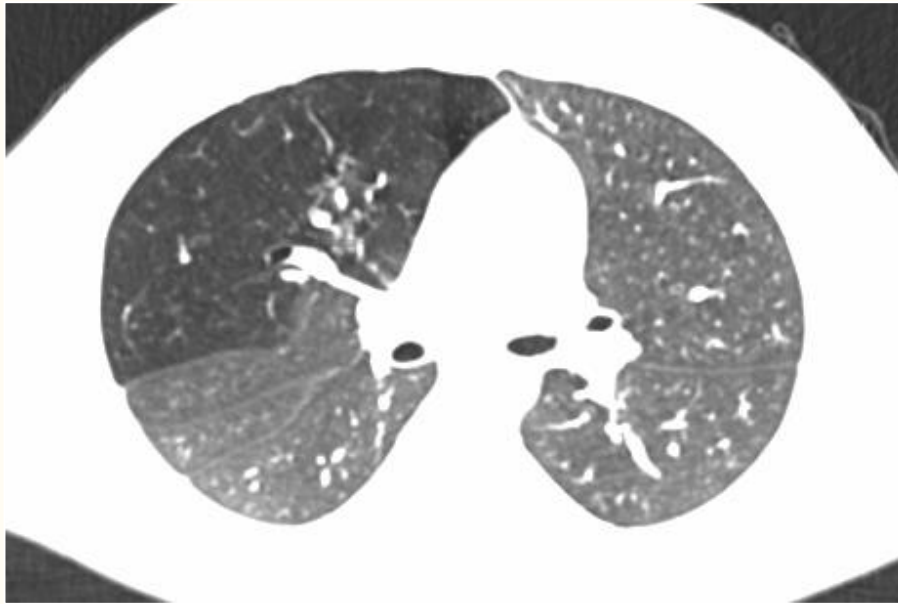
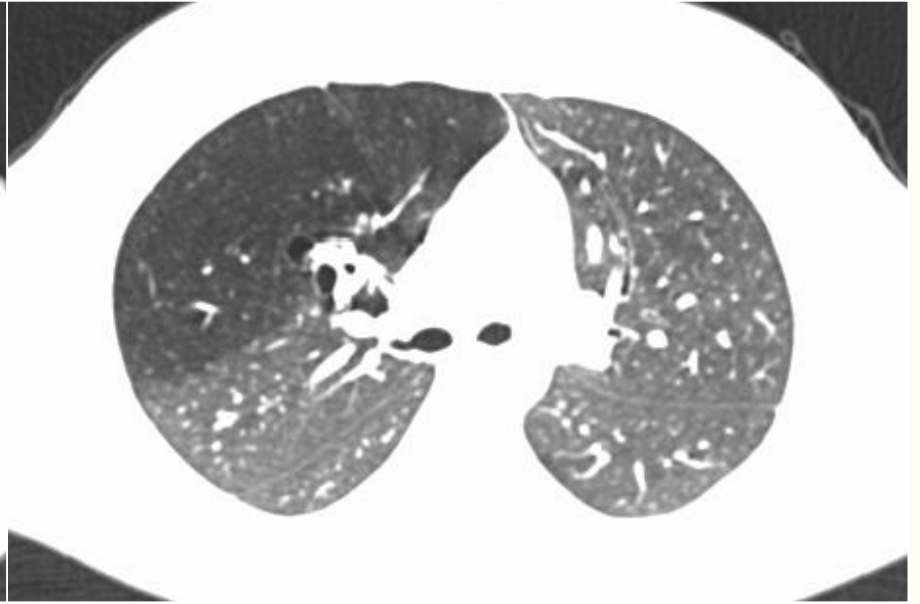
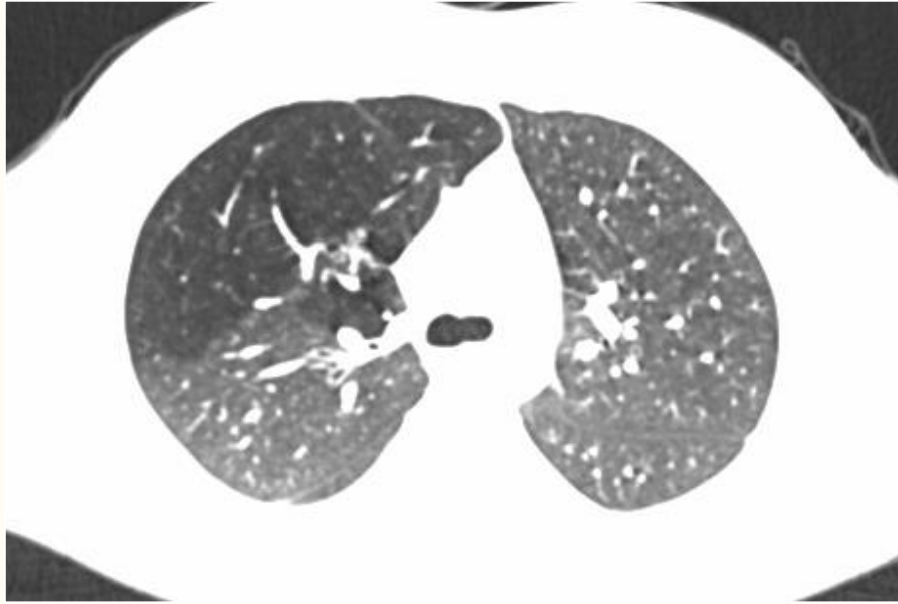
Mod



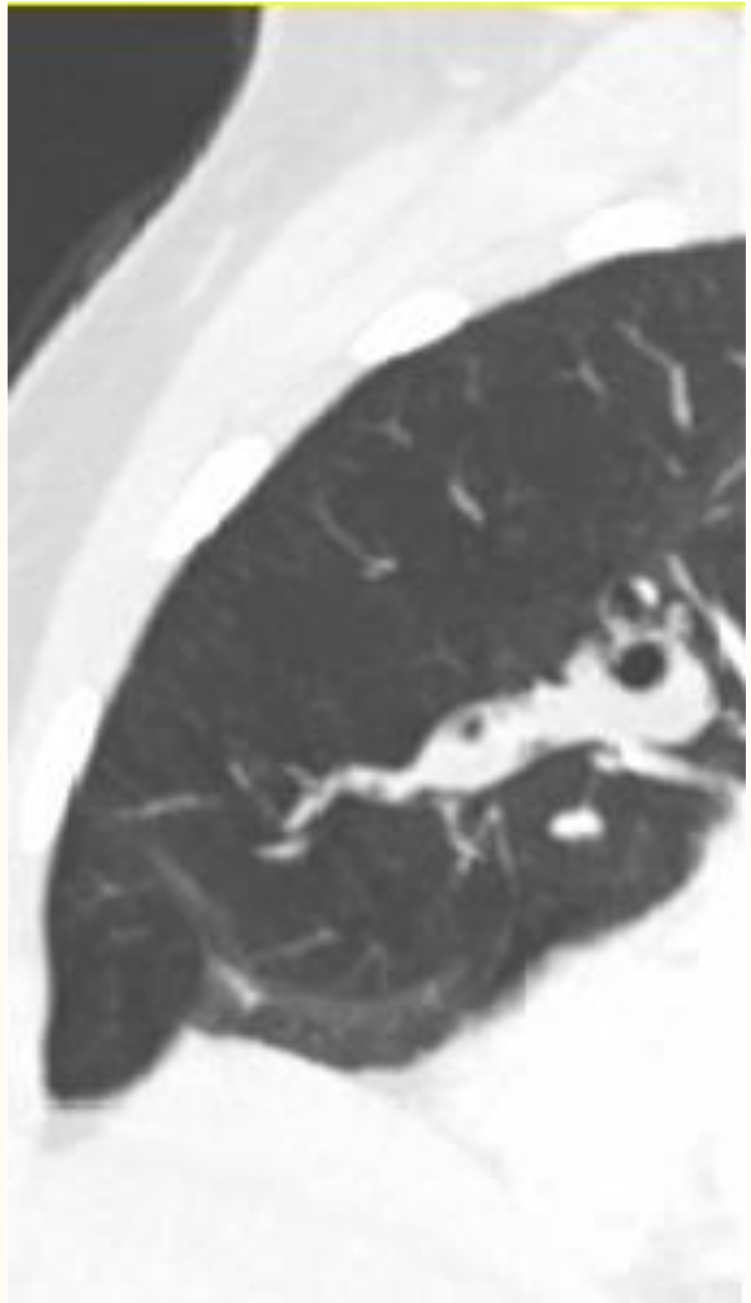
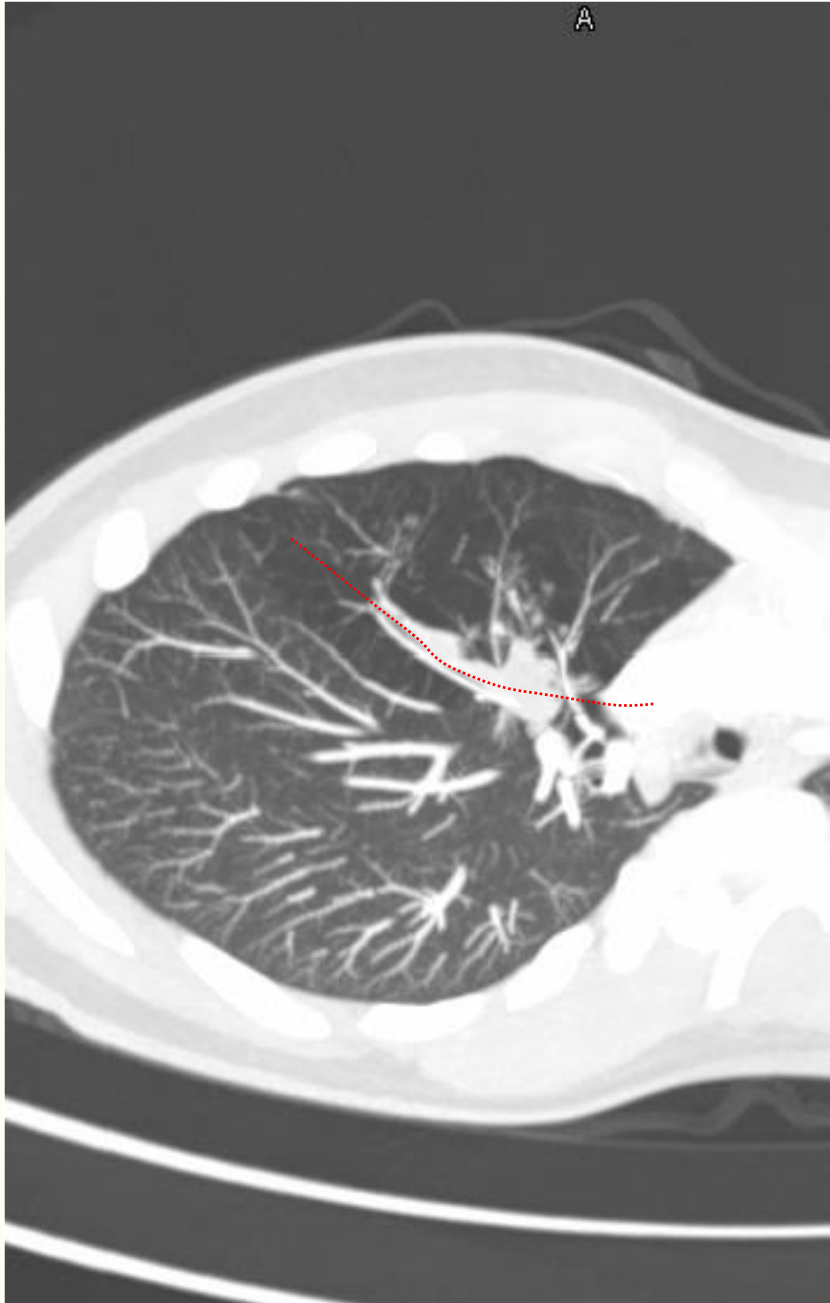:0.0
:0.0

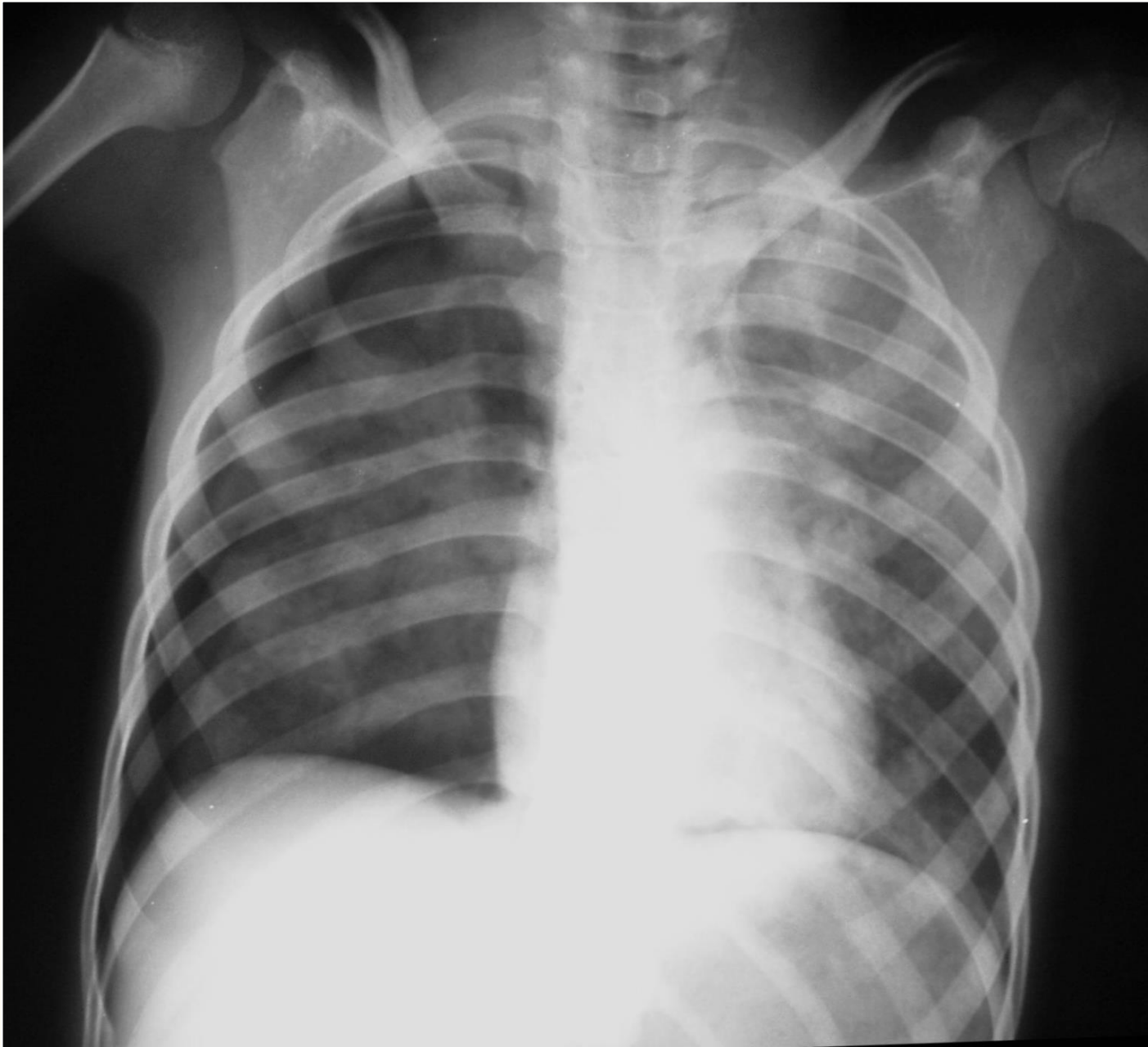
W033 AKCIGER pa

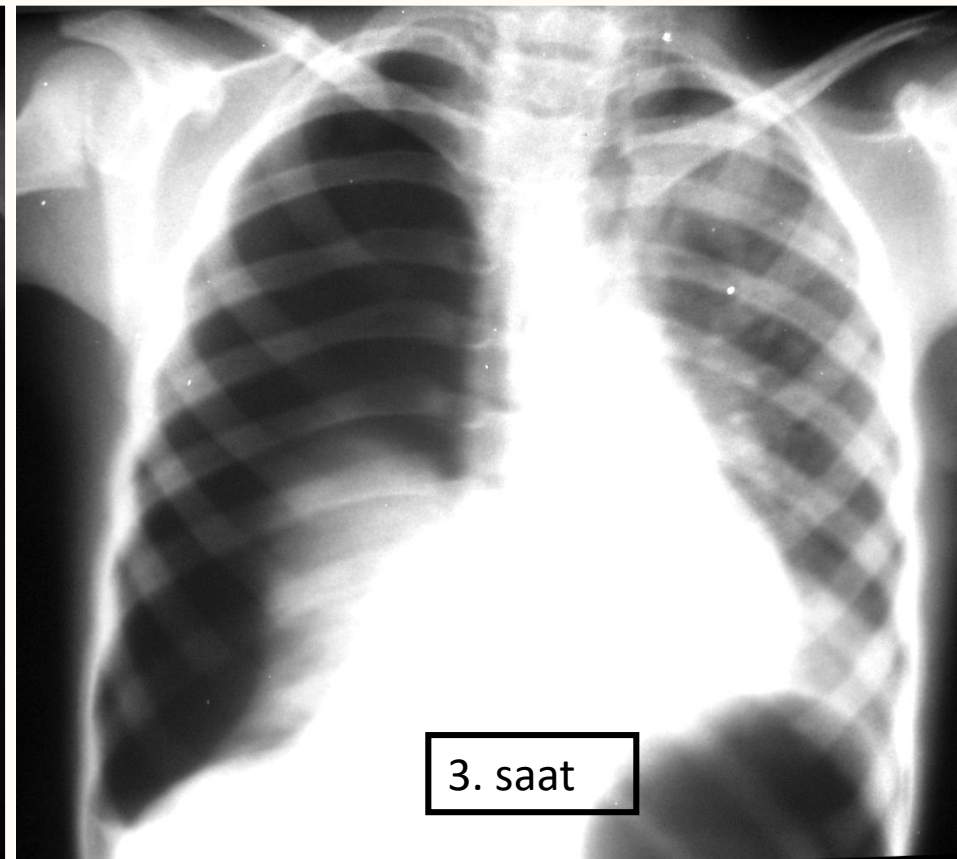
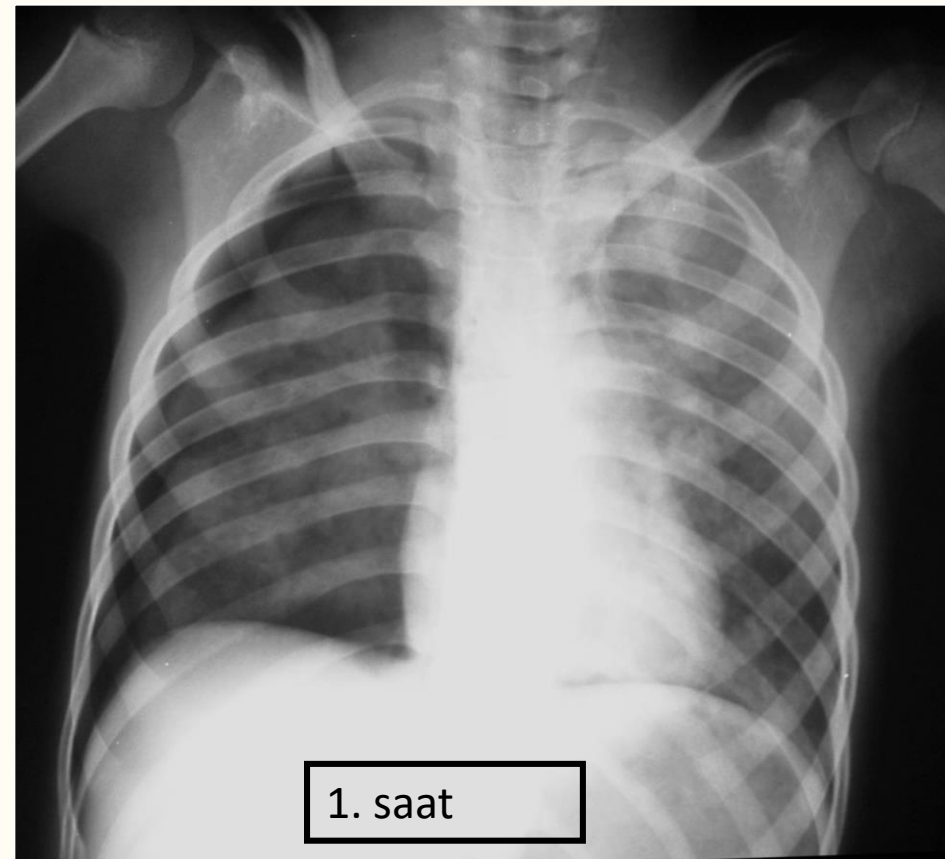

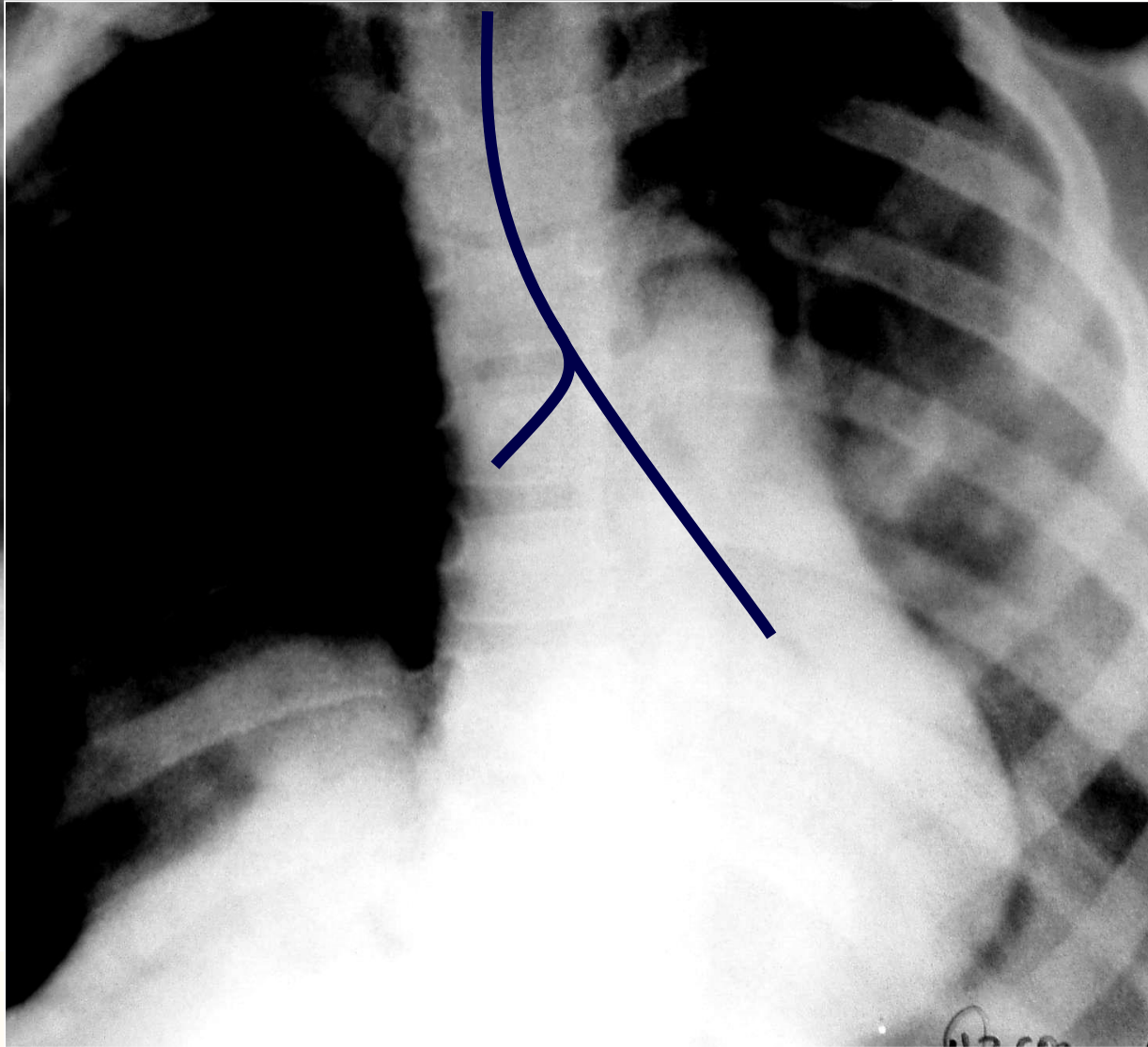
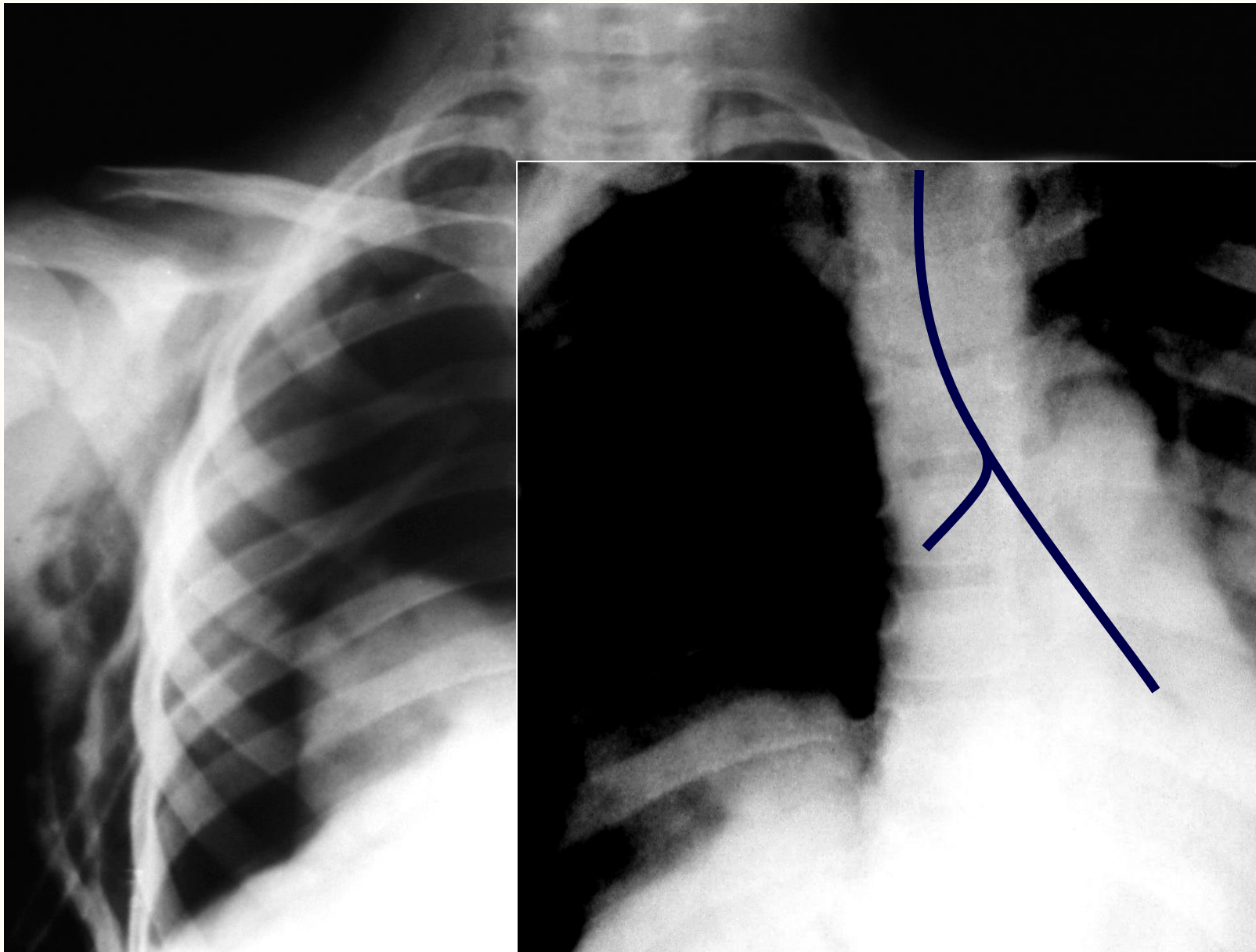


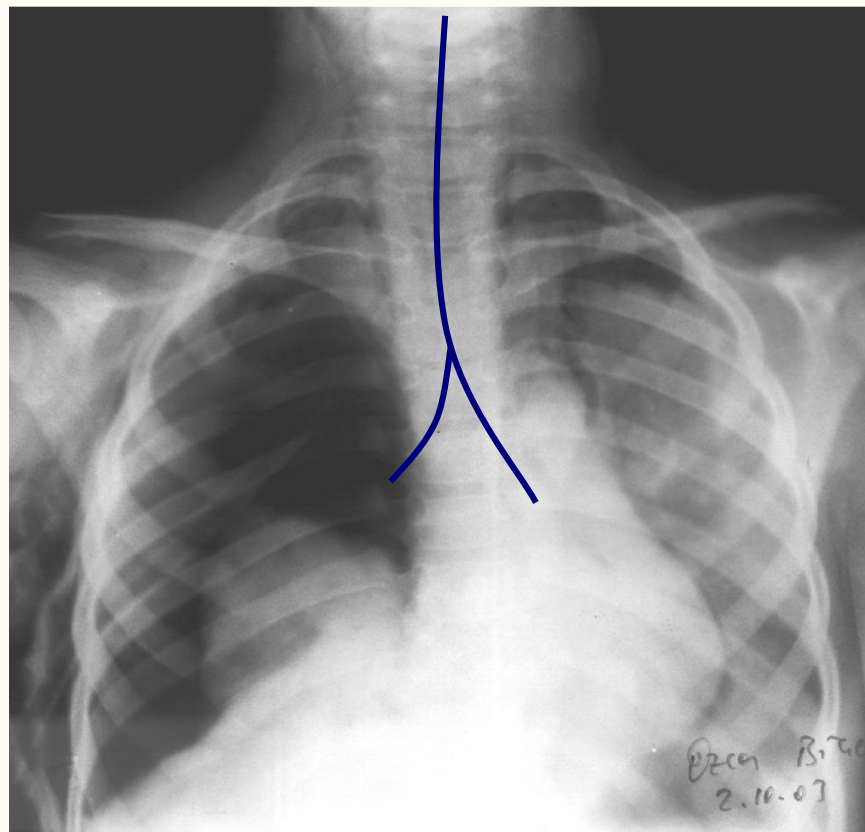
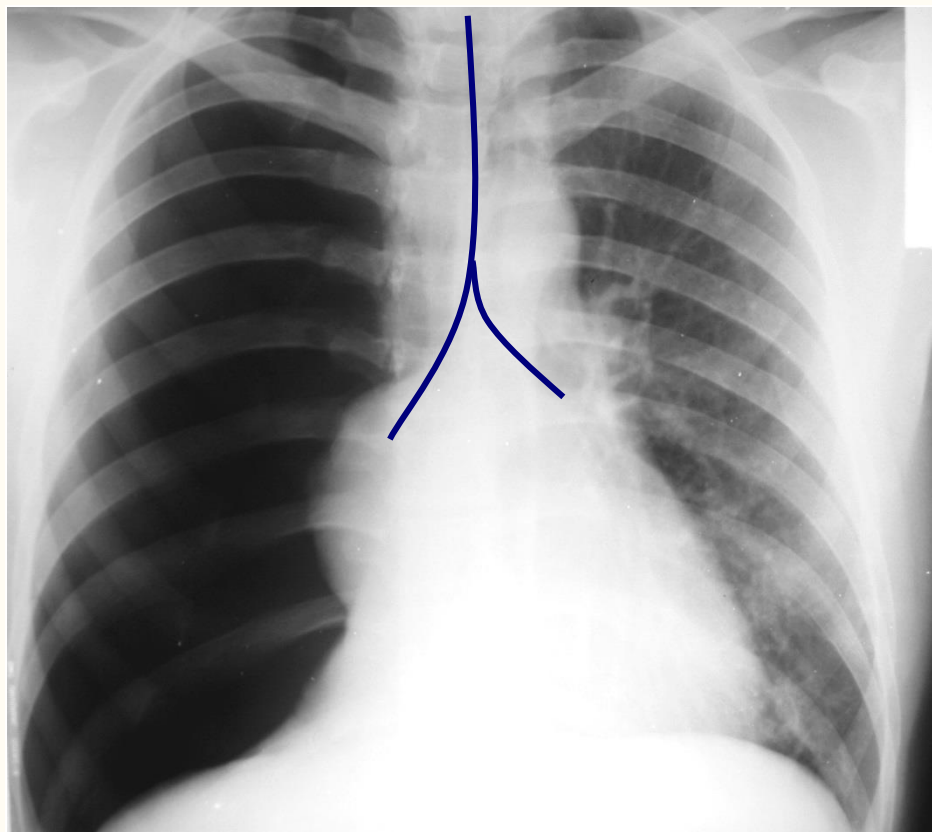
A

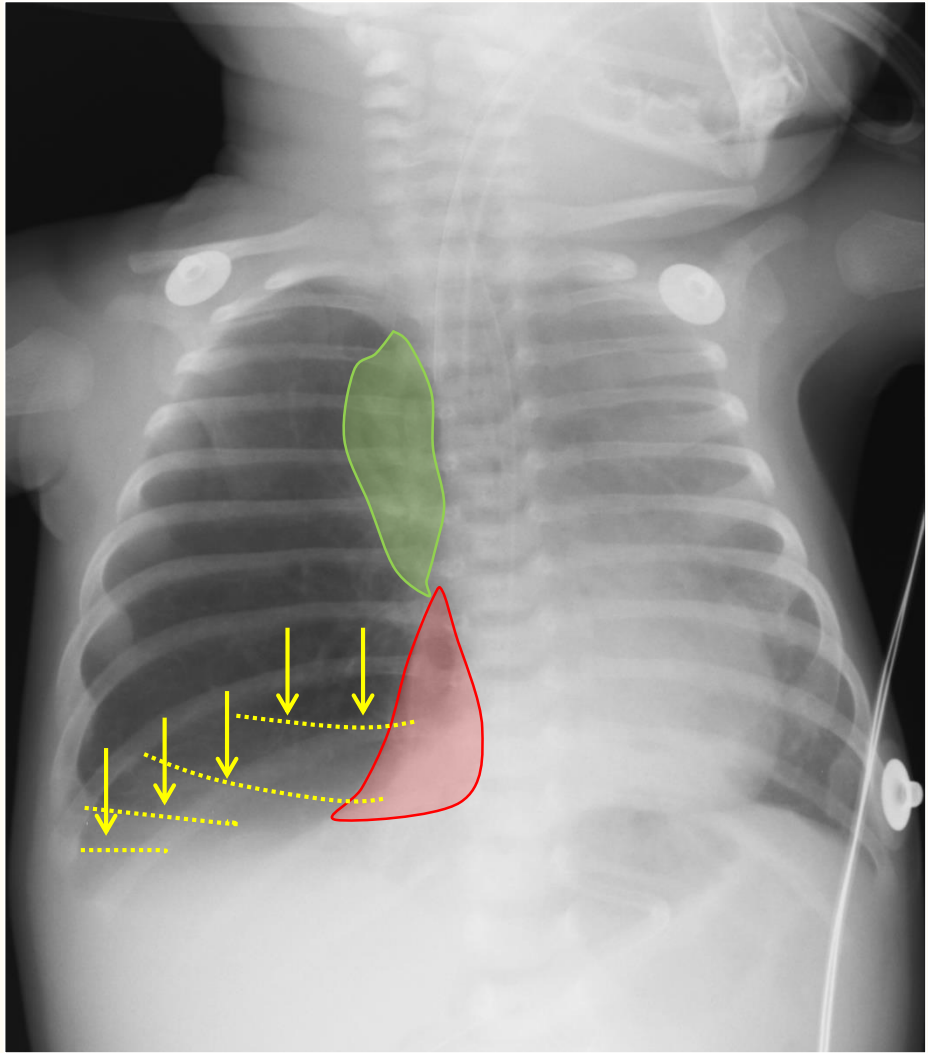
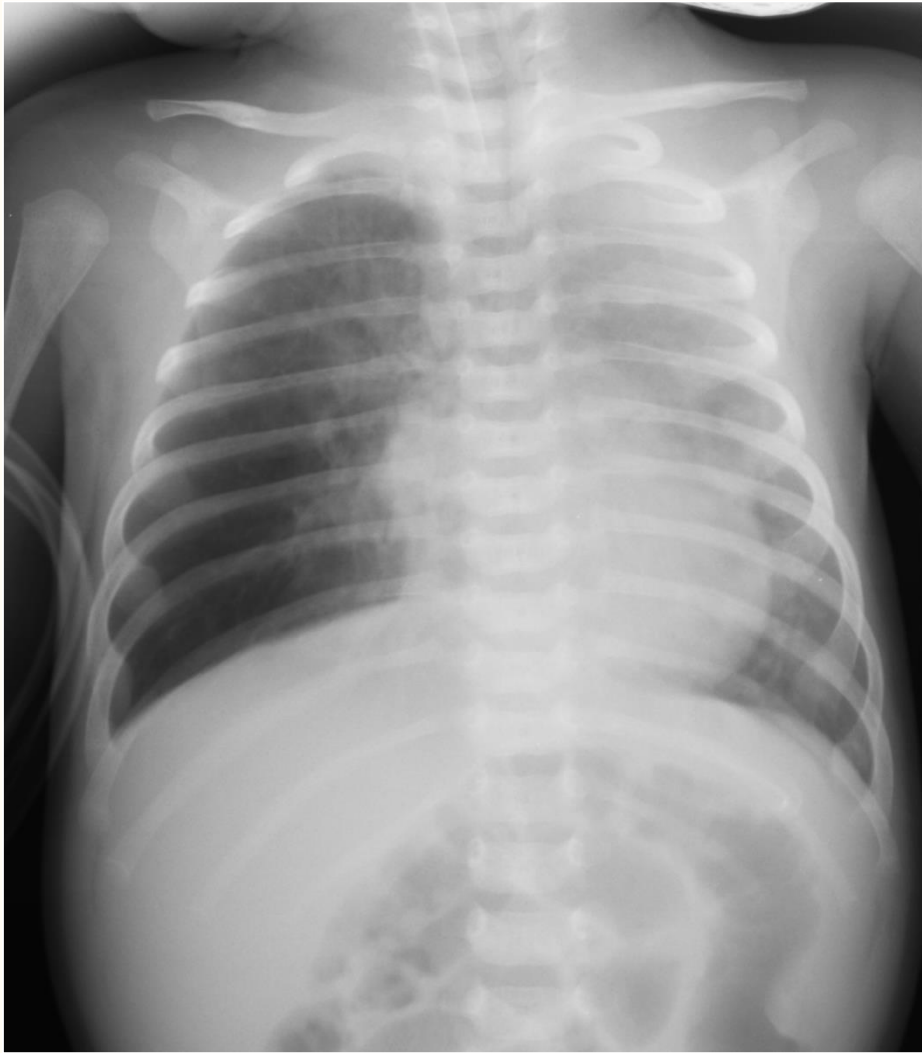

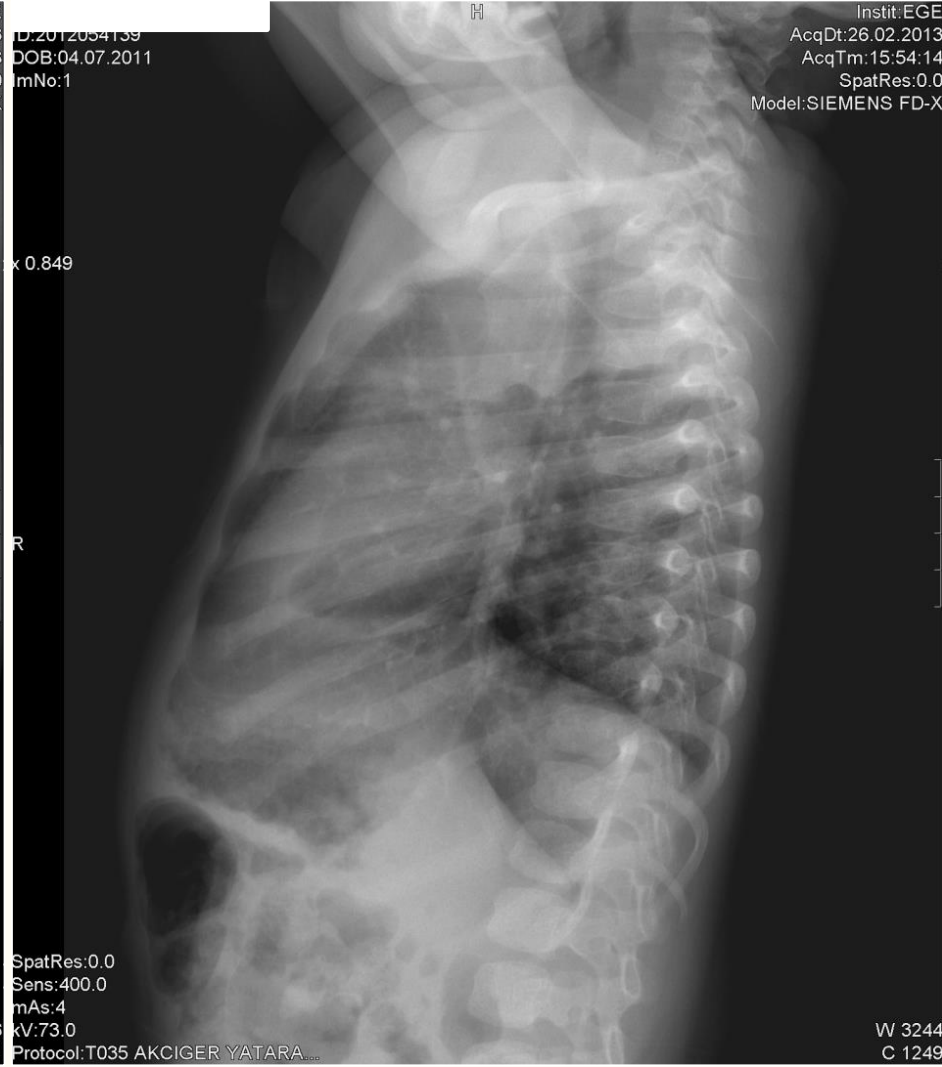
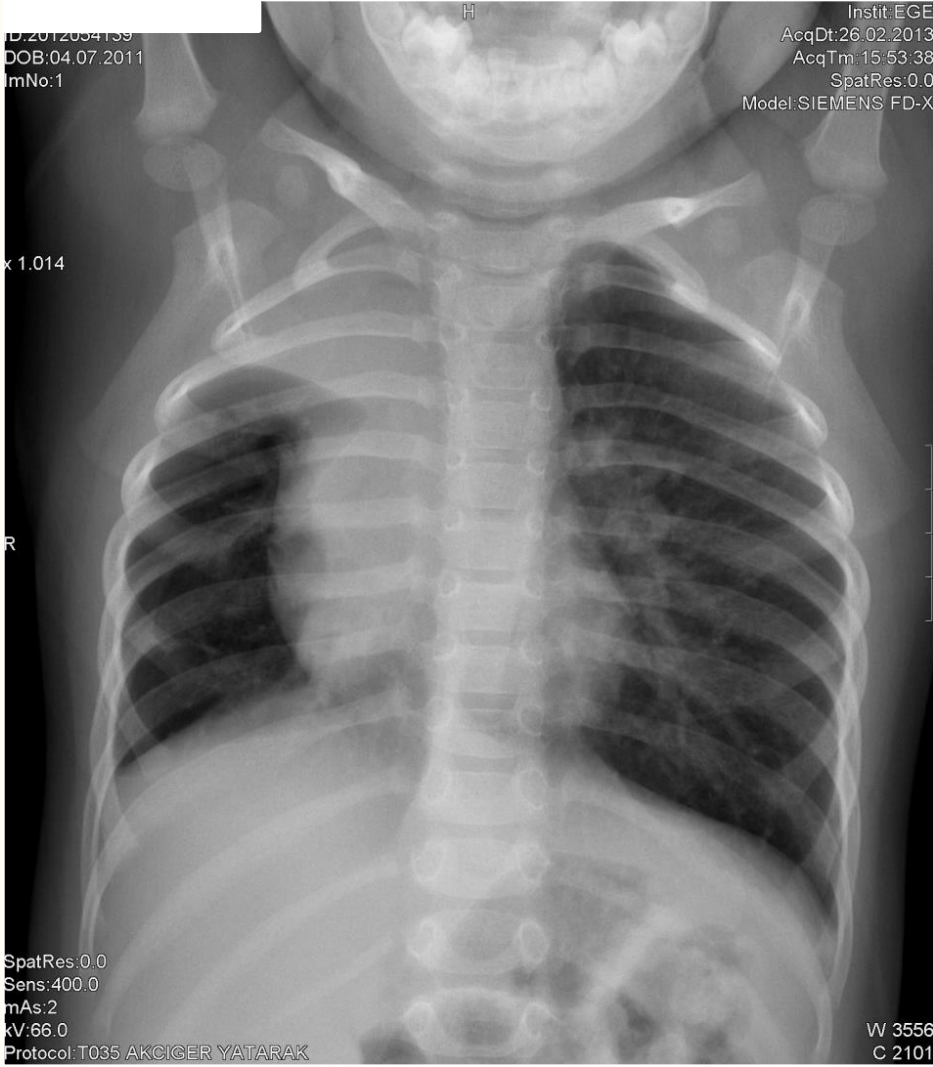












ID: 2012054139
DOB: 04.07.2011
ImNo: 1

Instit: D: 2012054139
AcqDt: 26.02.2013
AcqTm: 15:50
SpatRes: 0.0
Model: SIEMENS FD-X

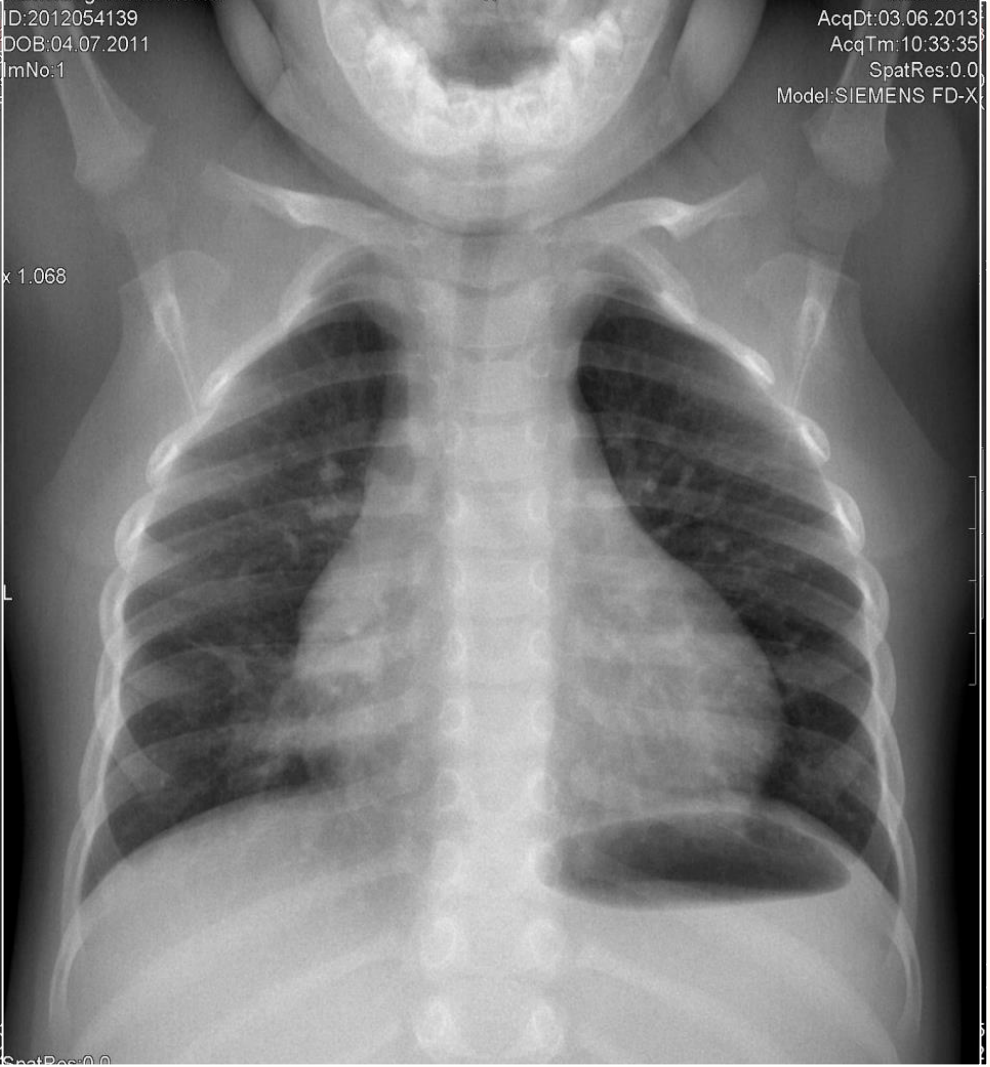
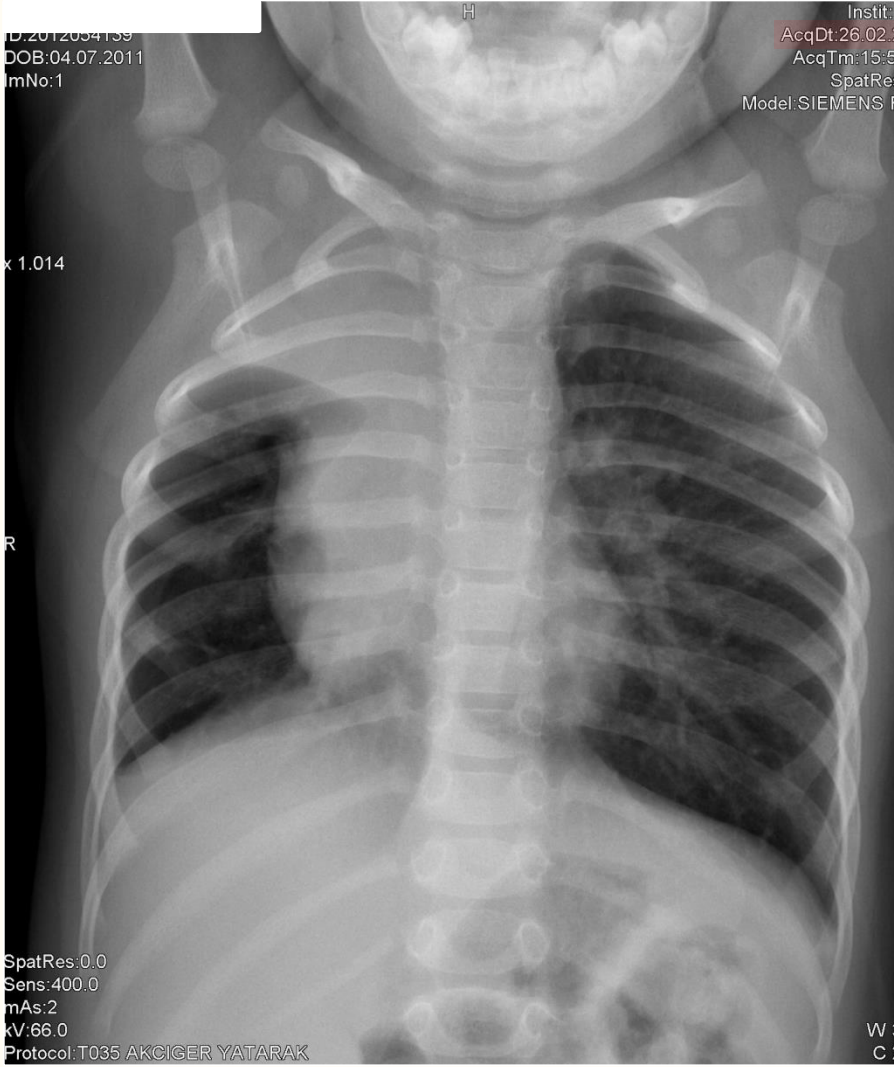
AcqDt: 03.06.2013
AcqTm: 10:33:35
SpatRes: 0.0
Model: SIEMENS FD-X

x 1.014

x 1.068

SpatRes: 0.0
Sens: 400.0
mAs: 2
kV: 66.0
Protocol: T035 AKCIGER YATARAK

W
C
SpatRes: 0.0



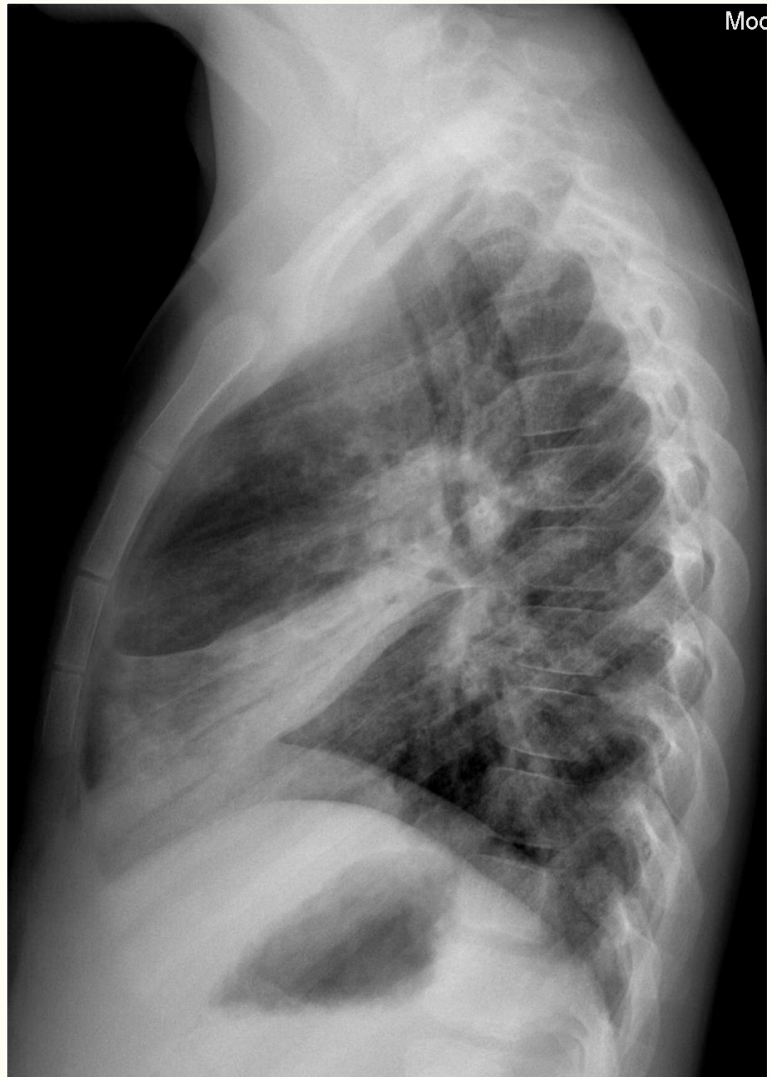
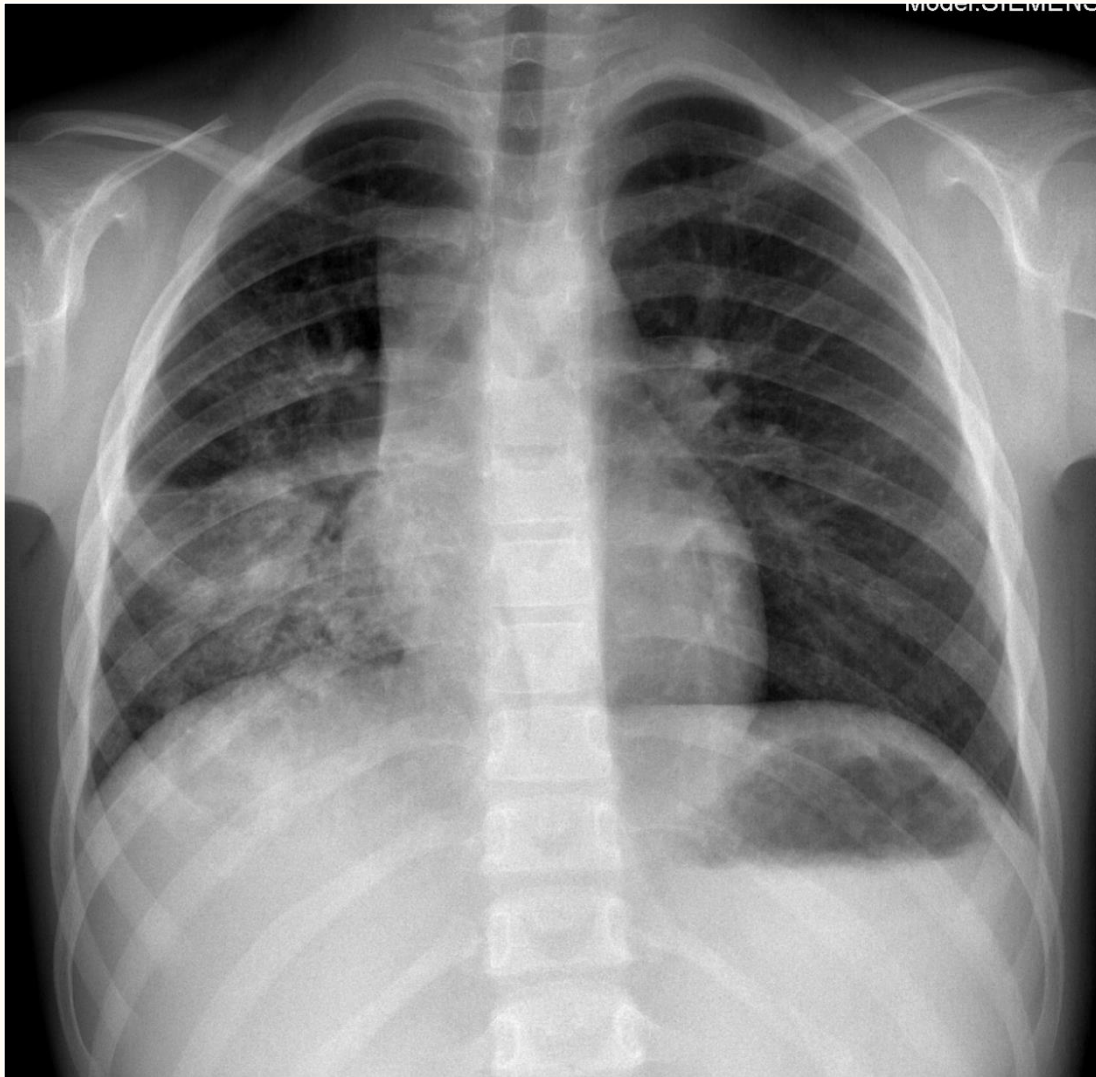
Silüet işareti

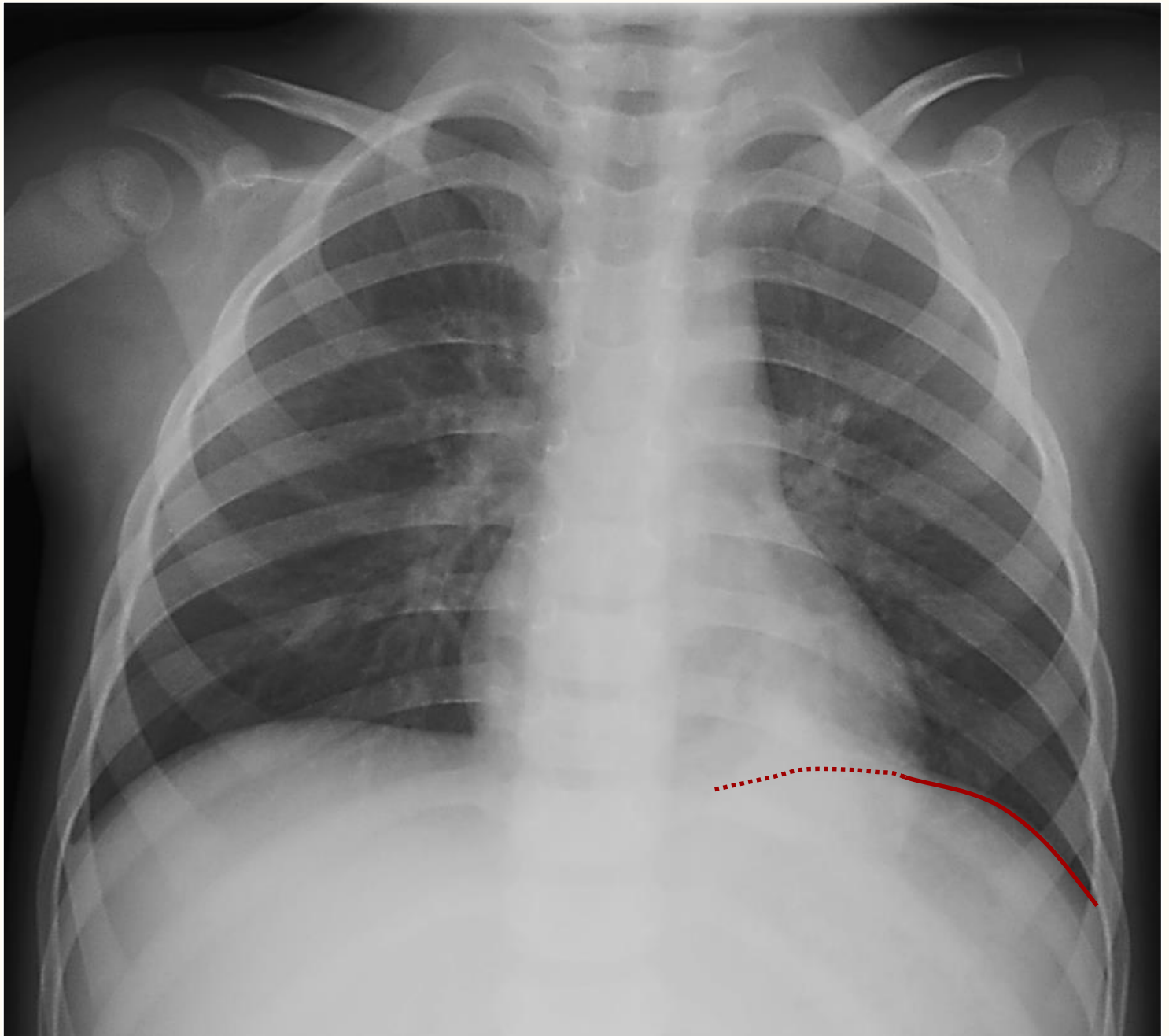
Toraksta

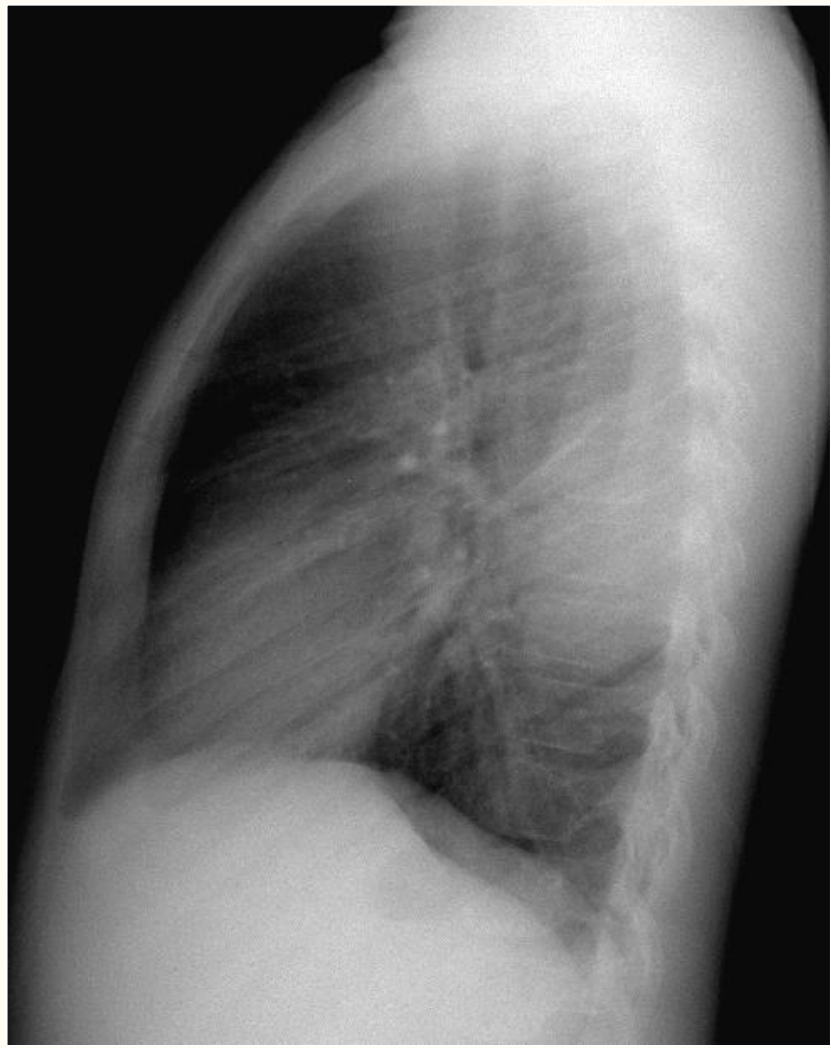
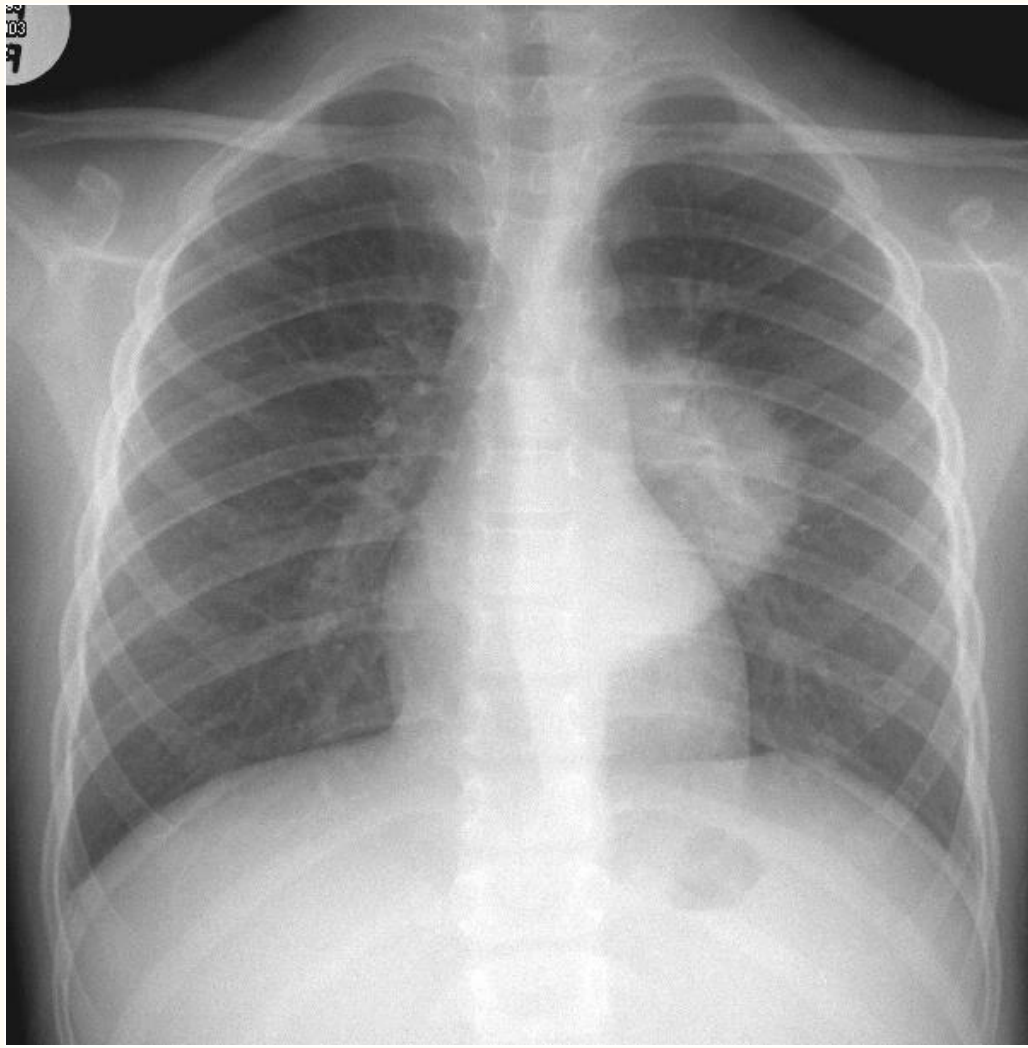
Birbiriyle eş (aynı) dansitede (renkte) olan oluşumlar,

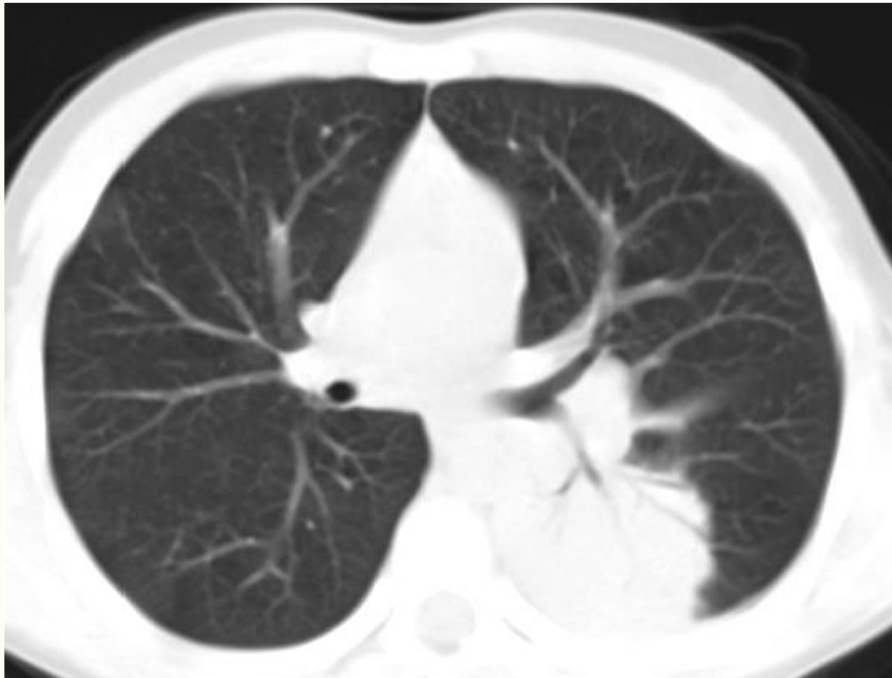
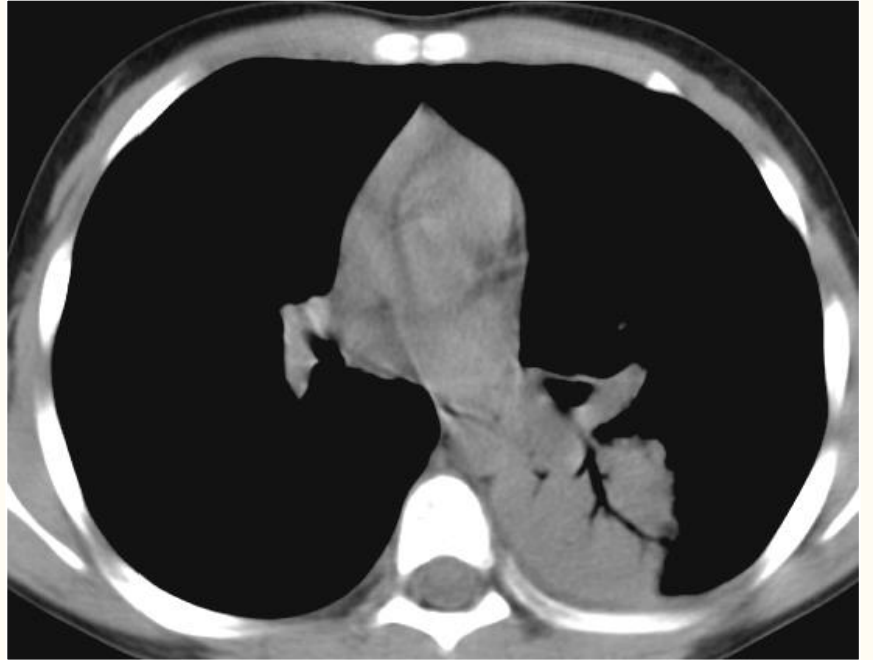
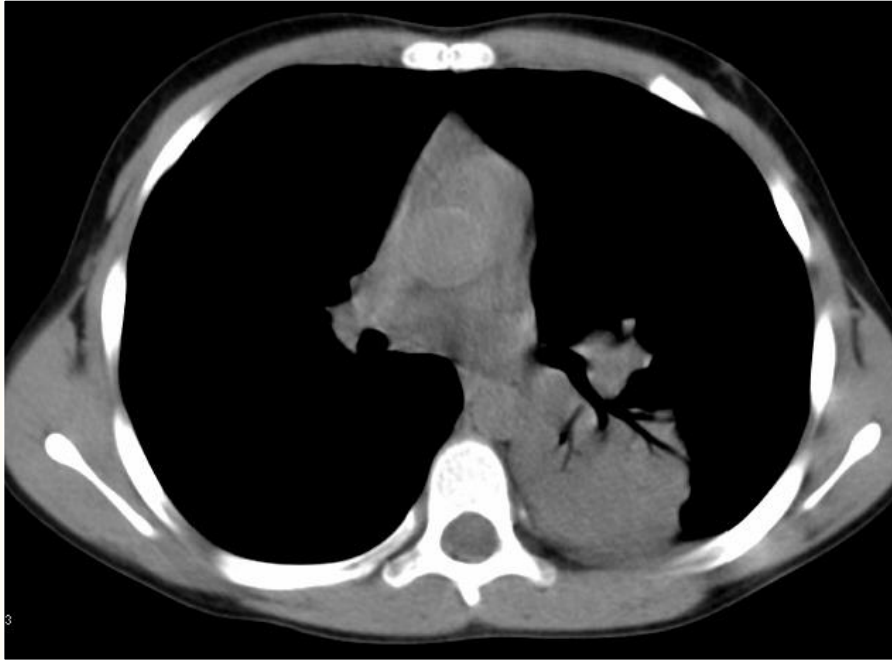
Anatomik olarak birbirlerine komşu (bitişik) ise

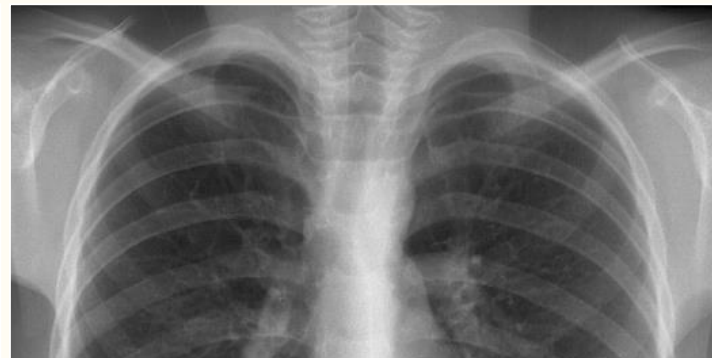
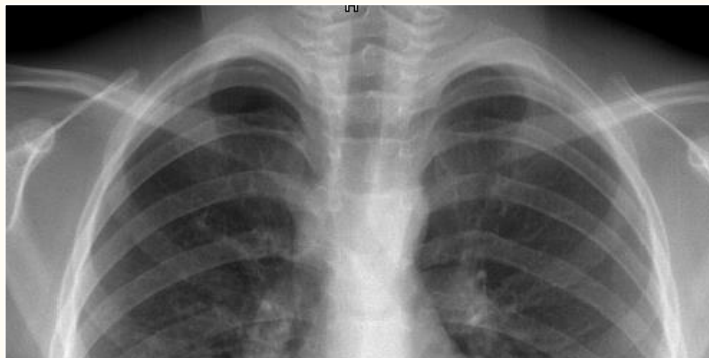
Birbirlerinin konturunu silerler (seçilmez hale getirirler)











Patient list

Filter: MR-ALL-New-Today
MR_BUGUN

Search: Patient name, Patient ID: 2014052424, Patient DOB: DD MM YYYY

Group worklist, Show all procedures

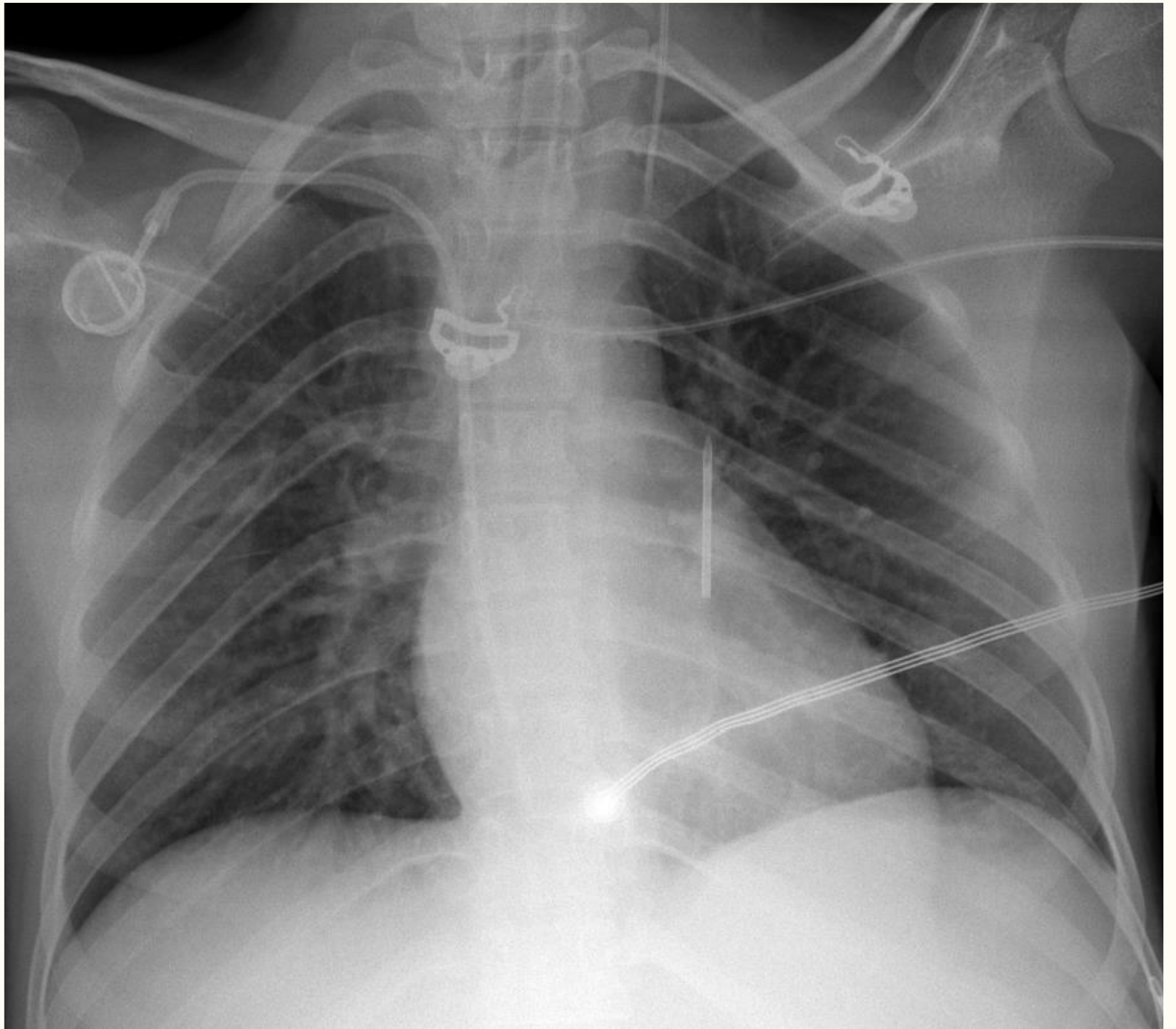
Patient name	Exam date/time	Modality	Organ	Procedure description
Emiklat Sureyya	02.12.2014 11:52:27	CTSR	CHEST	Toraks Anjio BT
Emiklat Sureyya	02.12.2014 10:05:31	CR		CR.544
Emiklat Sureyya	15.04.2014 13:20:00	CR		W AKCIGER 2 YONLU
Emiklat Sureyya	09.04.2014 17:59:00	CR		W AKCIGER 2 YONLU

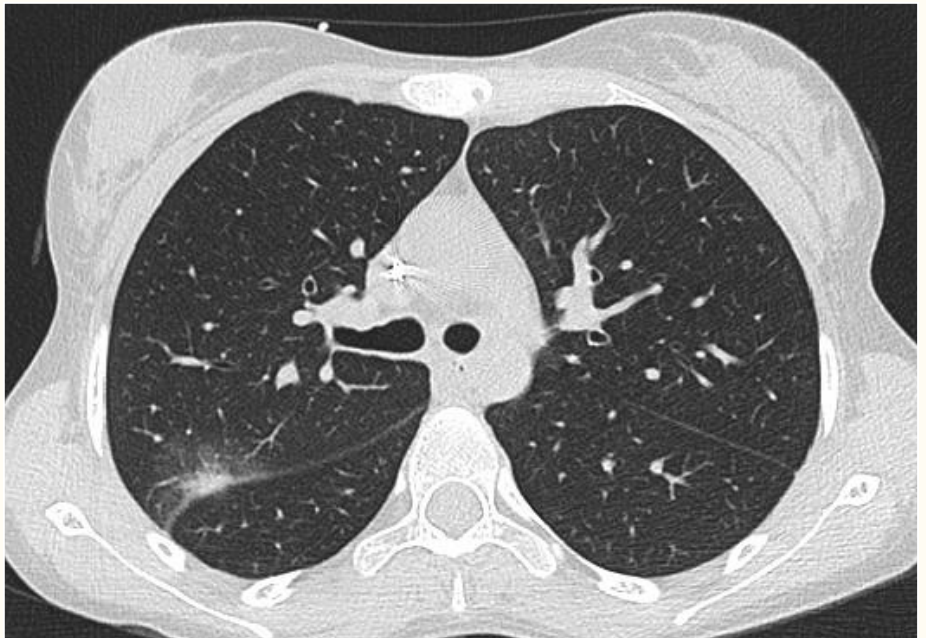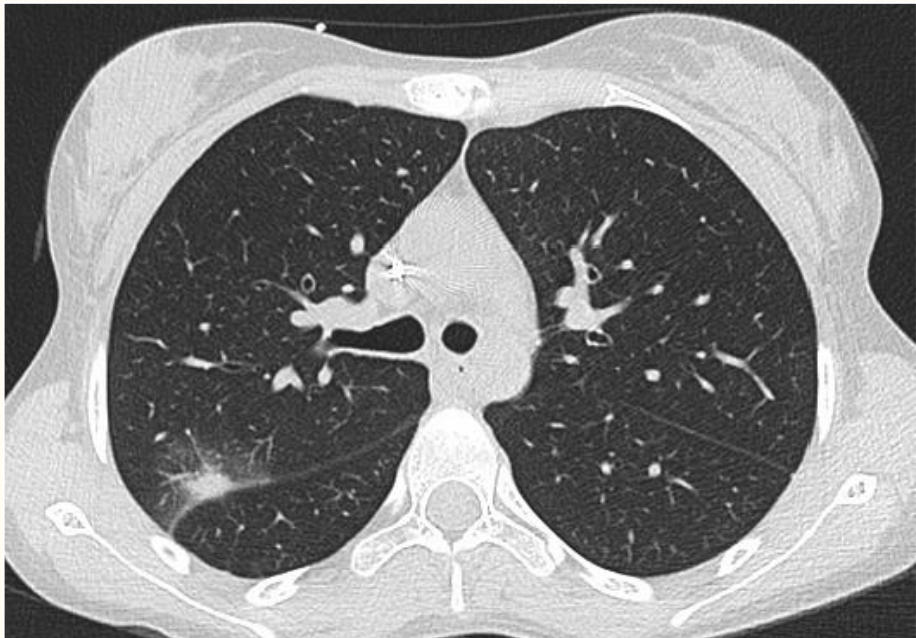
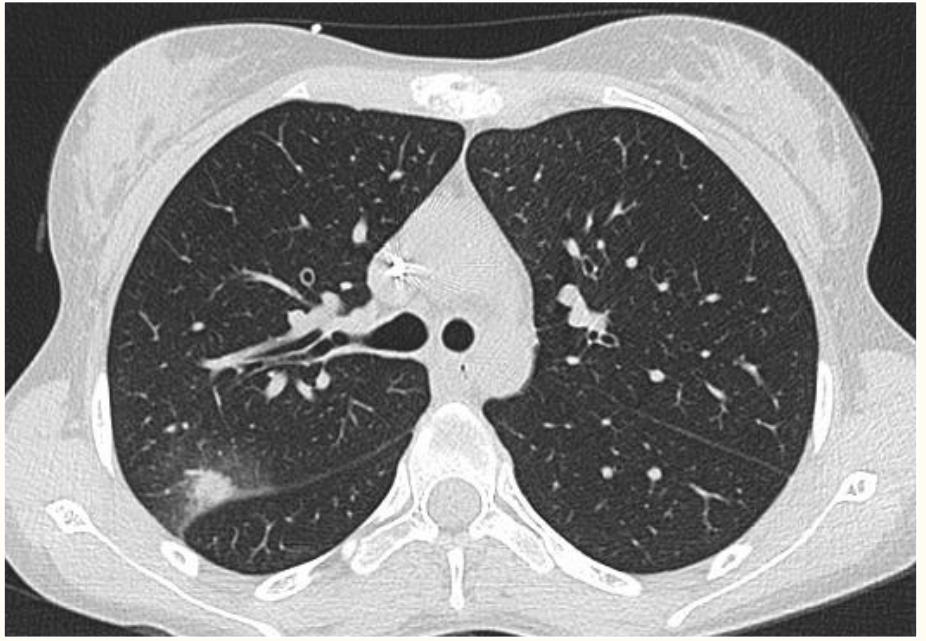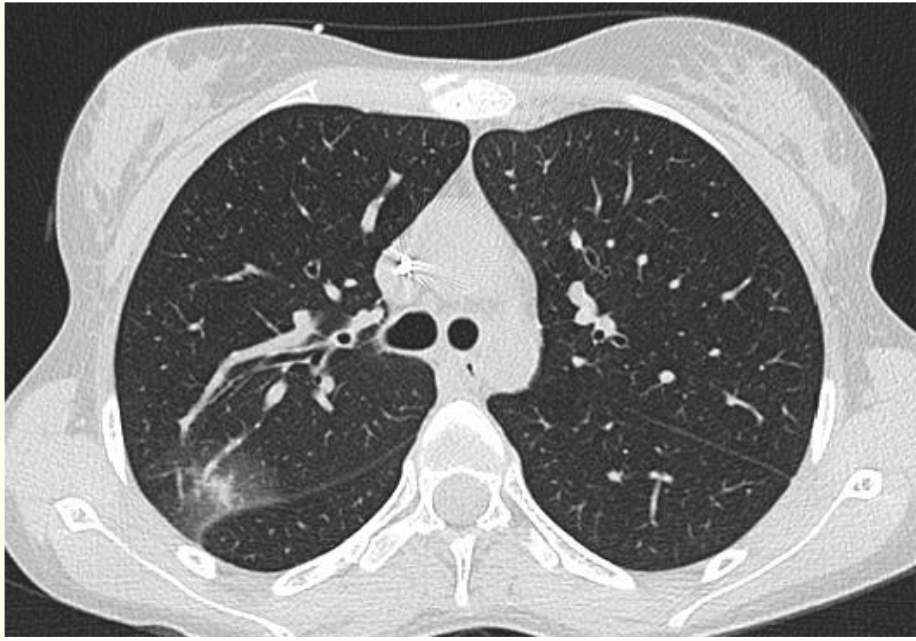
Report			Series			
Organ	Series description	Modality	Series no.	Number of Images/Frames	Archive status	S
CHEST	W033 AKCIGER pa	CR	1	1/1	NEARLINE	0
	W033 AKCIGER pa	CR	1	1/1	NEARLINE	0
	Topogram 0.6 T20s	CT	1	3/3	NEARLINE	0
	W033 AKCIGER lat.	CR	2	1/1	NEARLINE	0

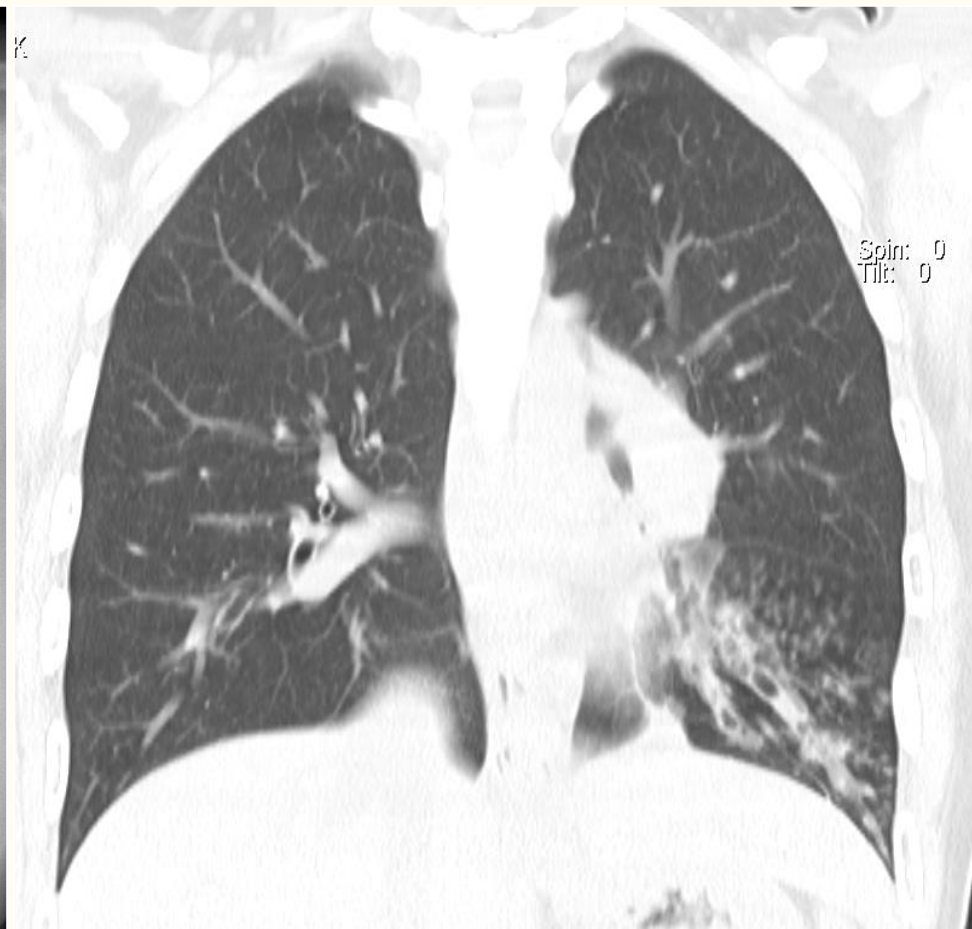
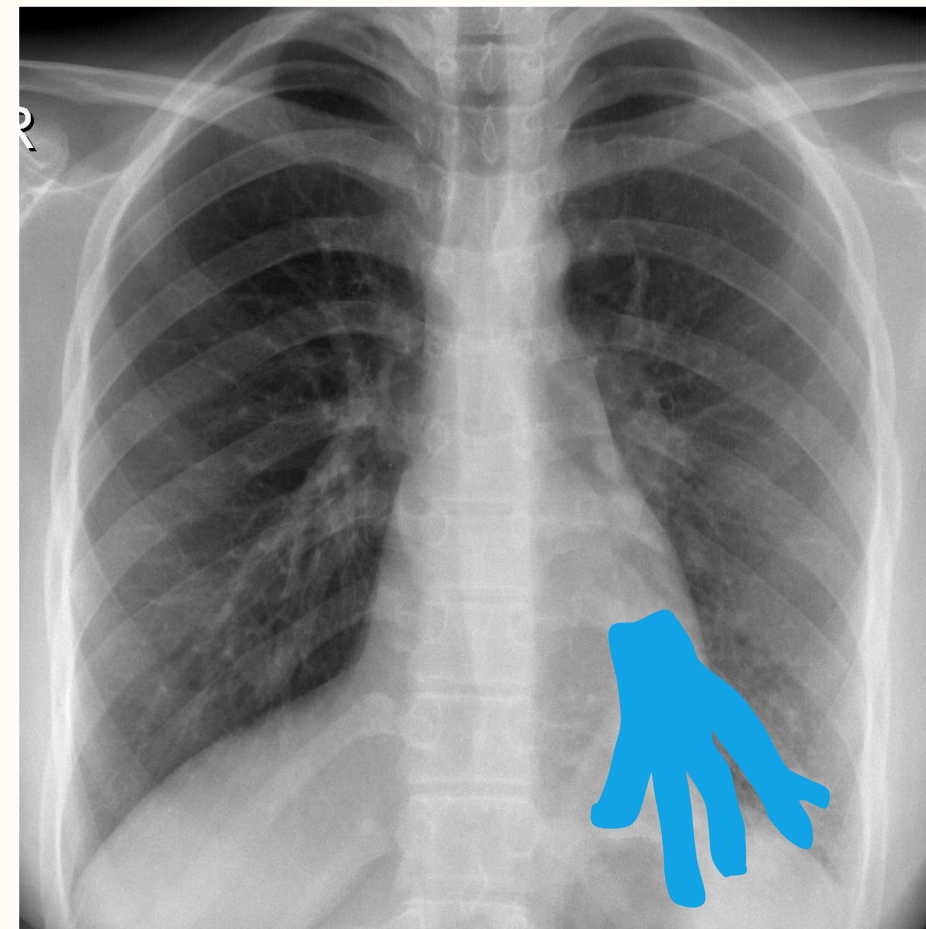
Getting worklist: completed

2 Aralık

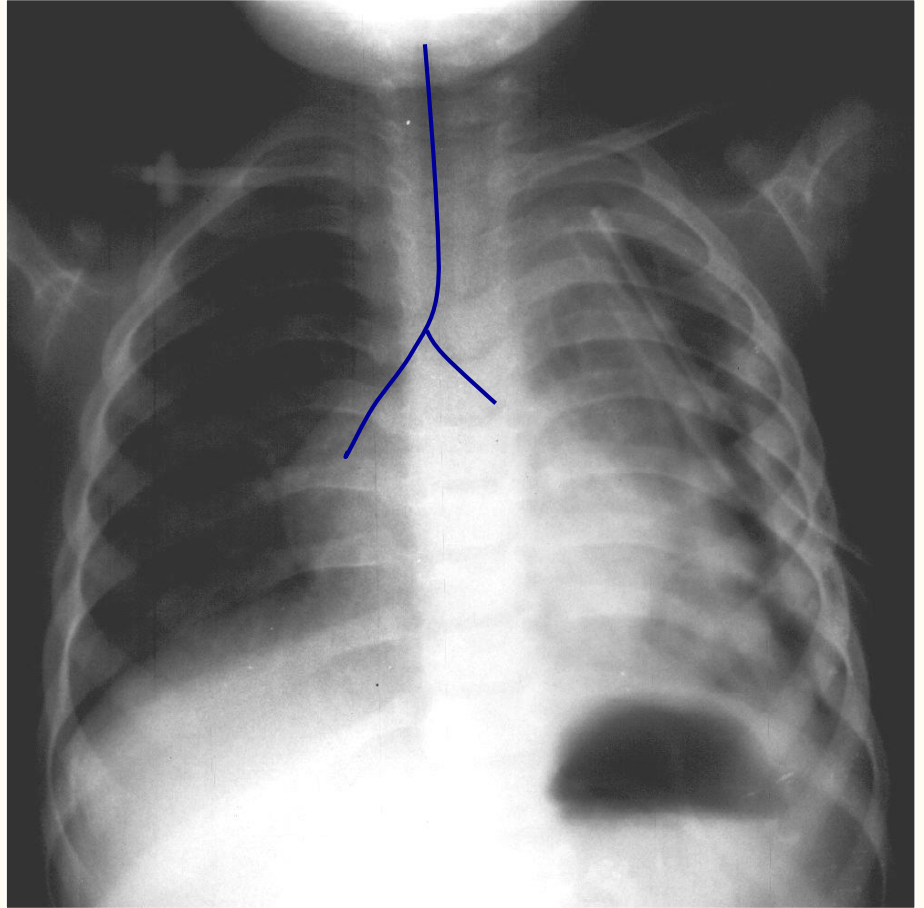
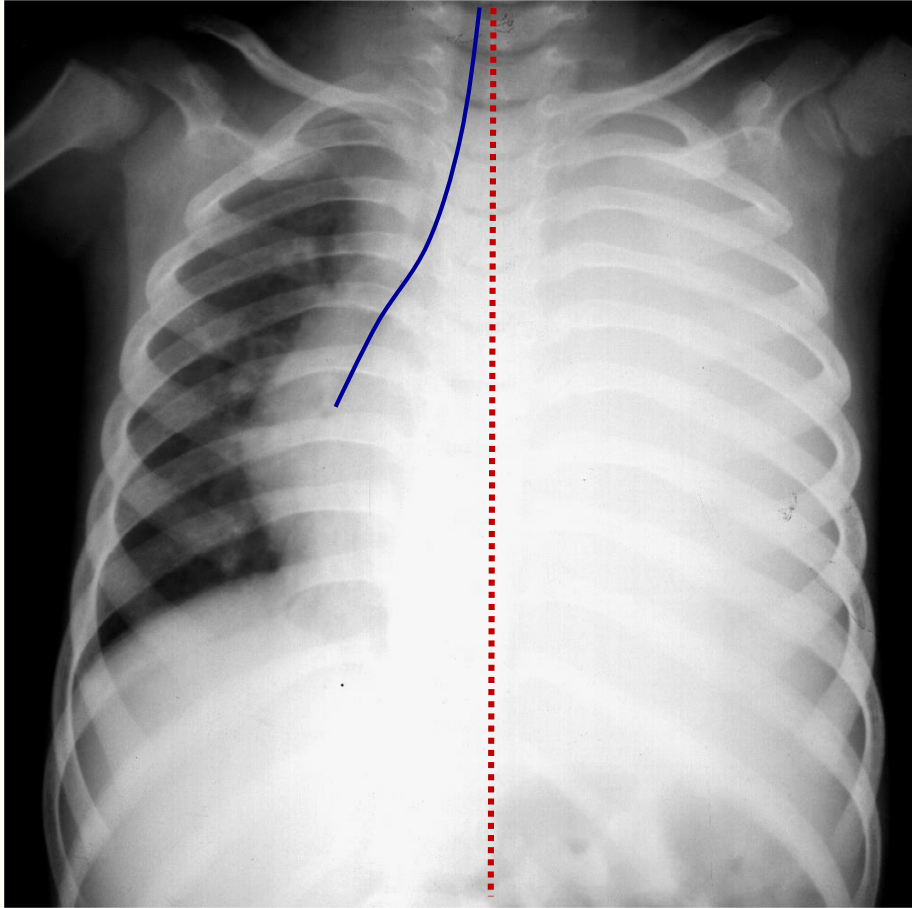
2 Aralık

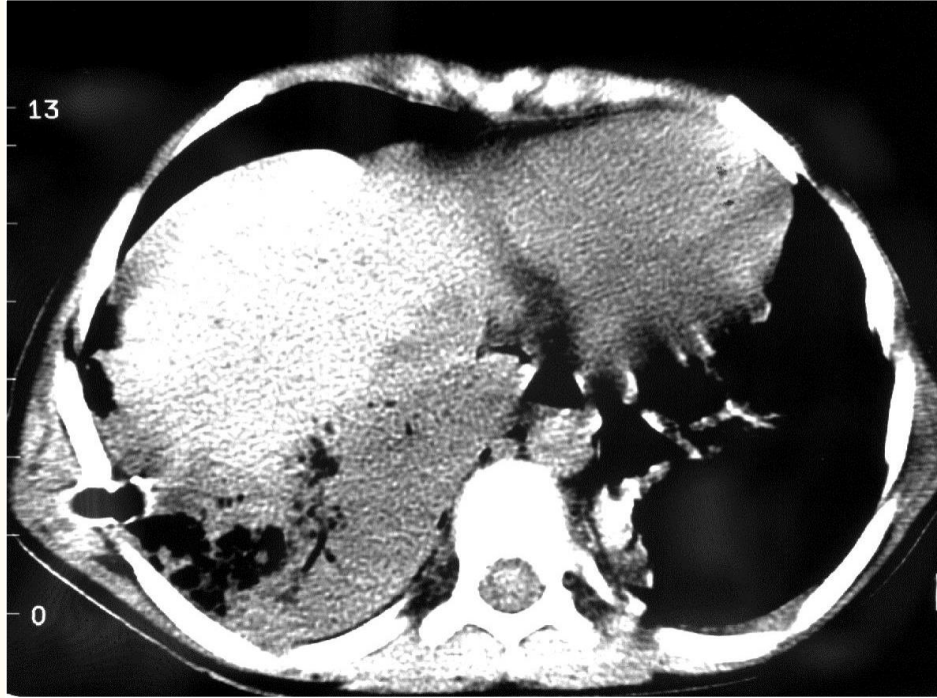
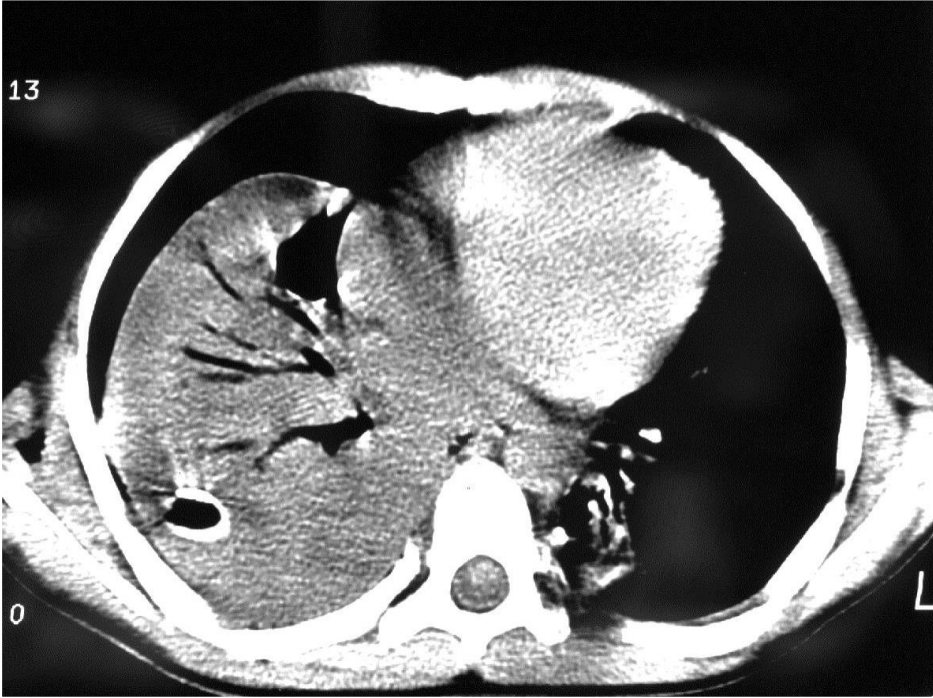
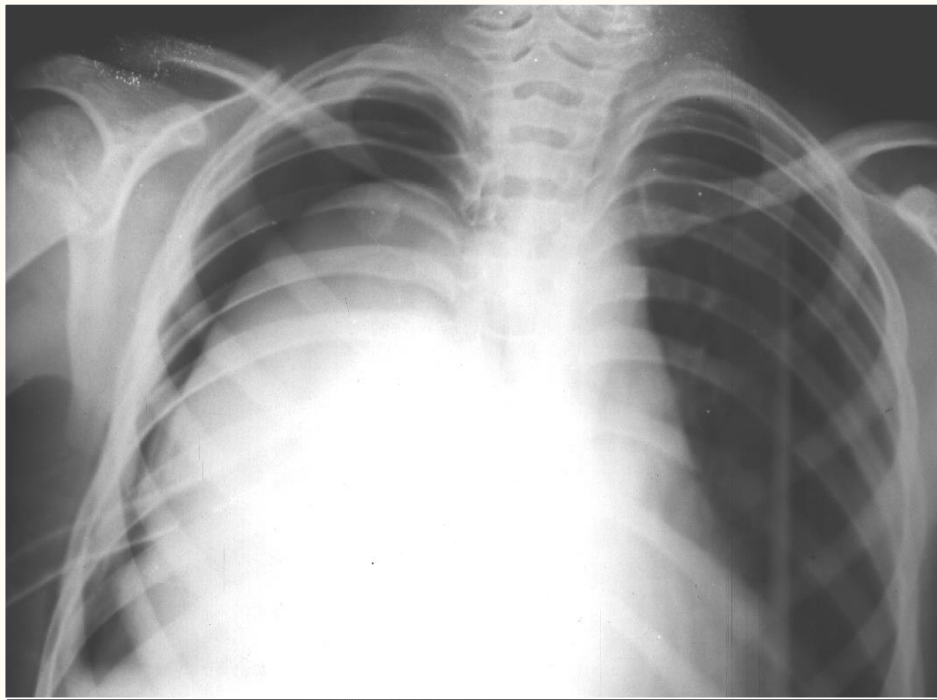
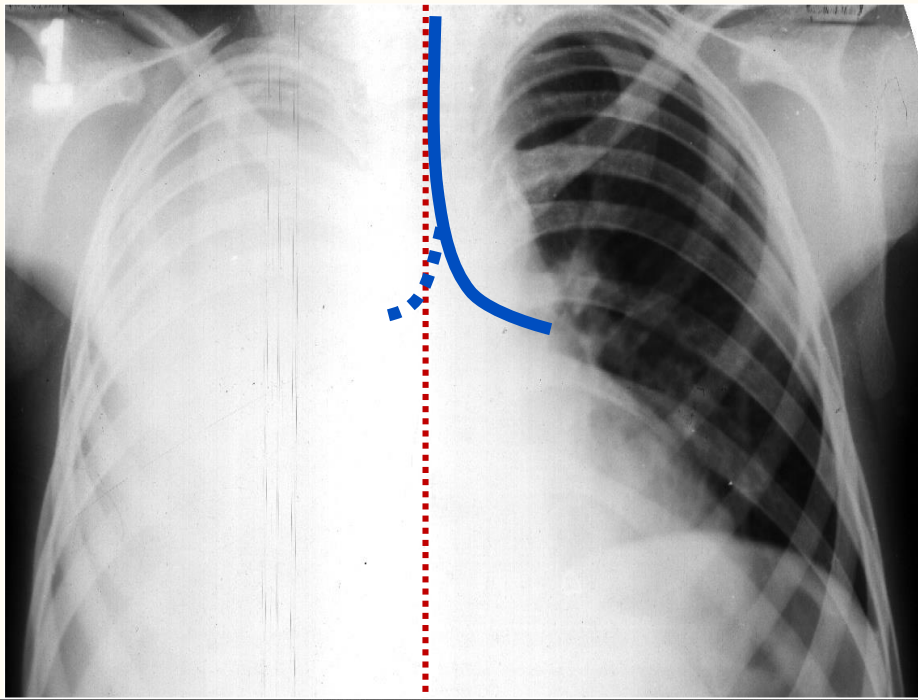


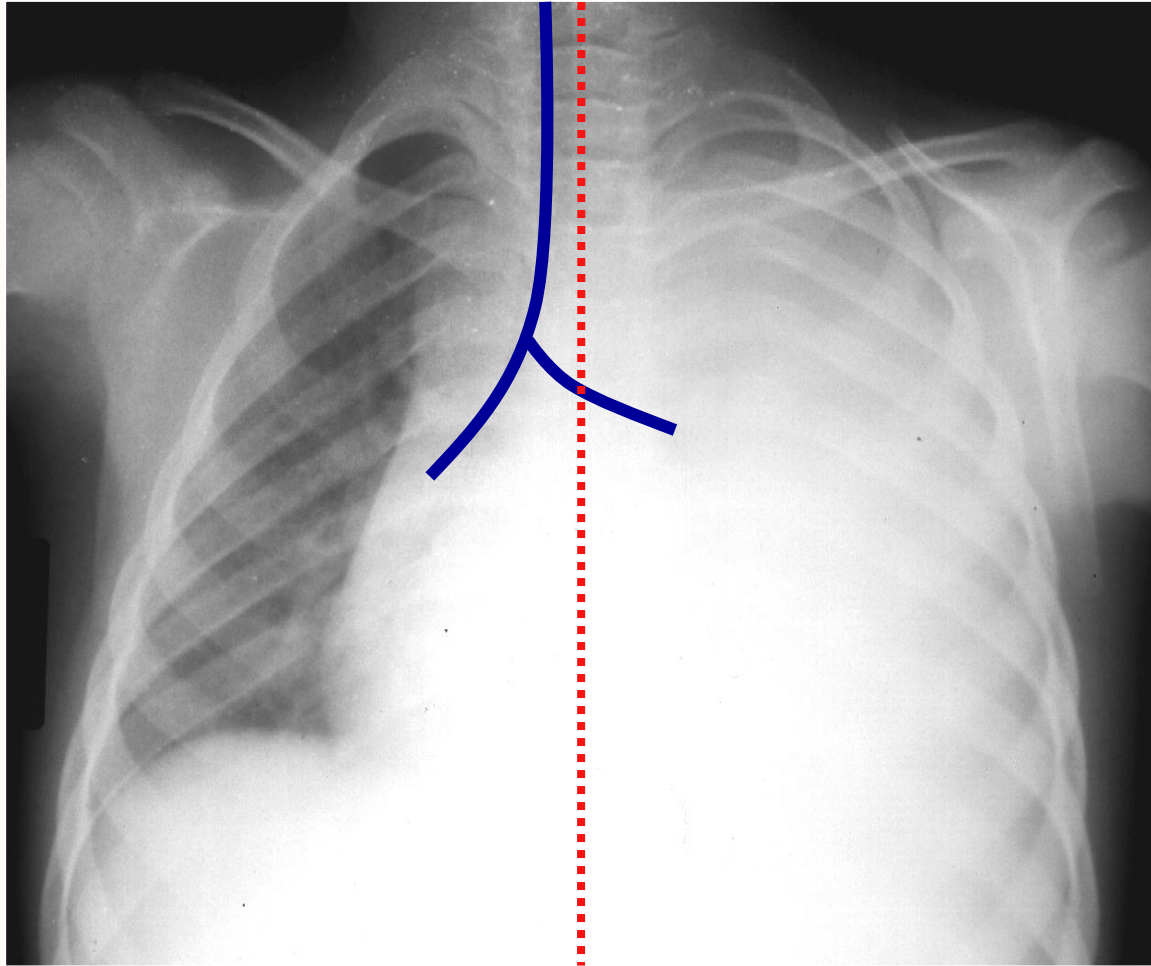


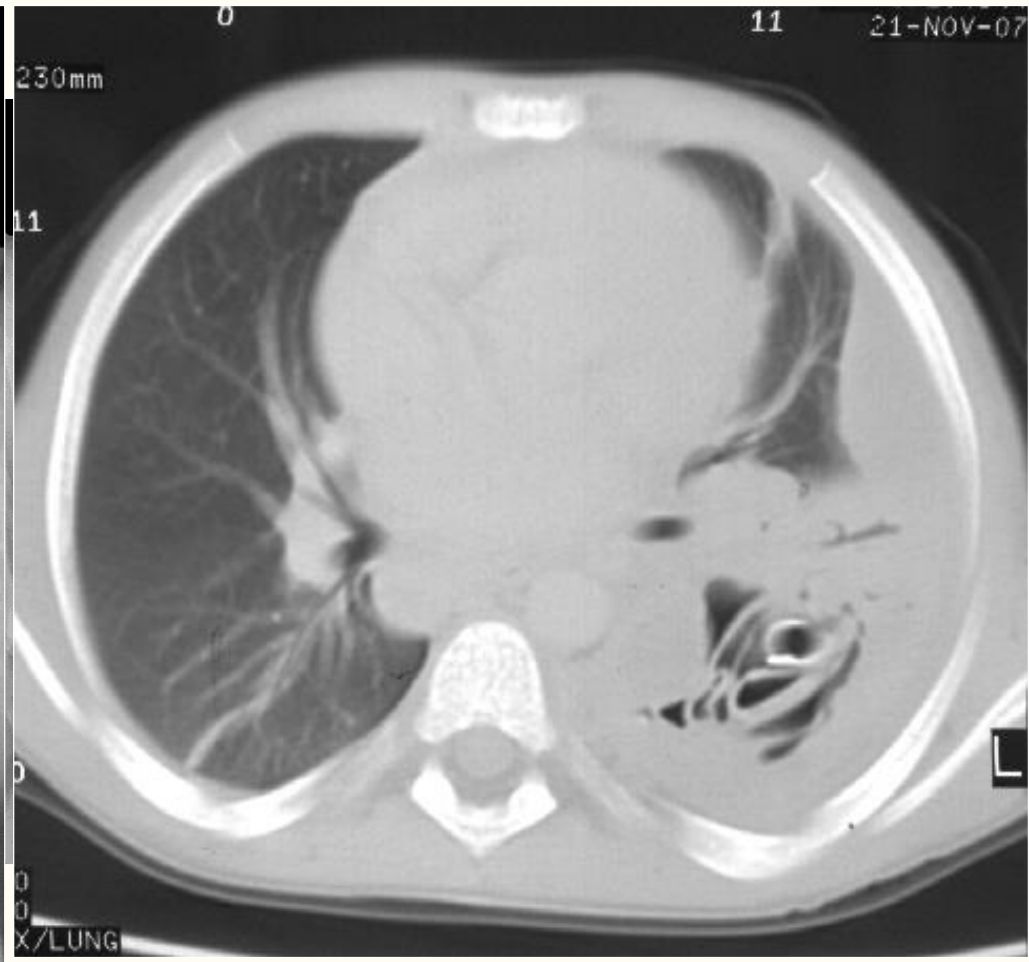
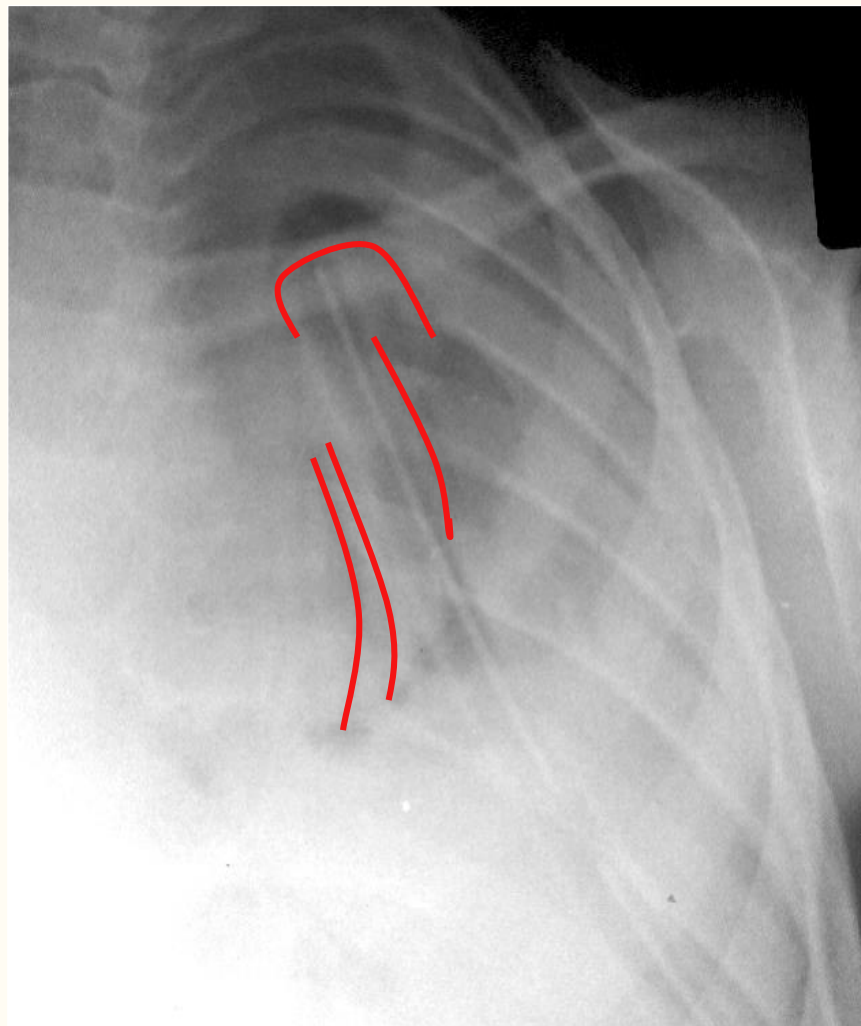


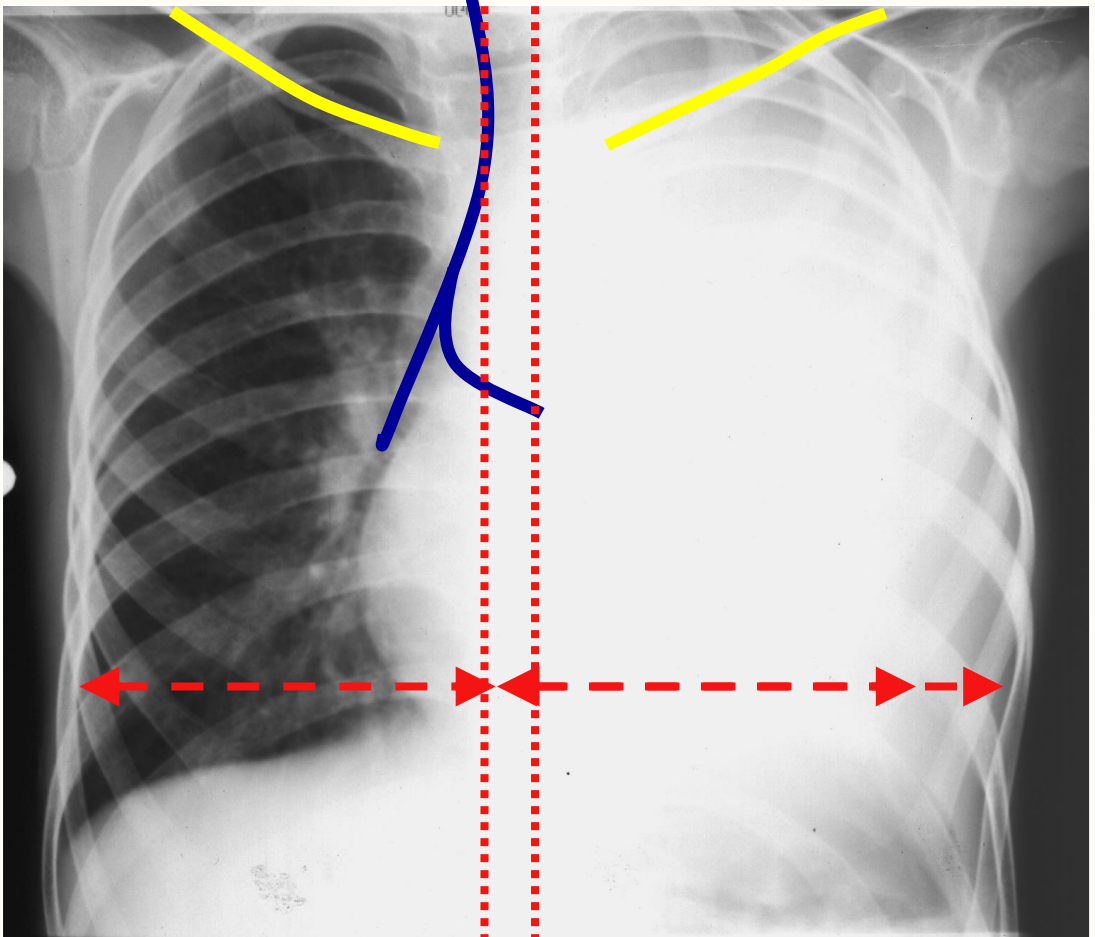
Bronşektazi – Eldivenli Parmak işareti

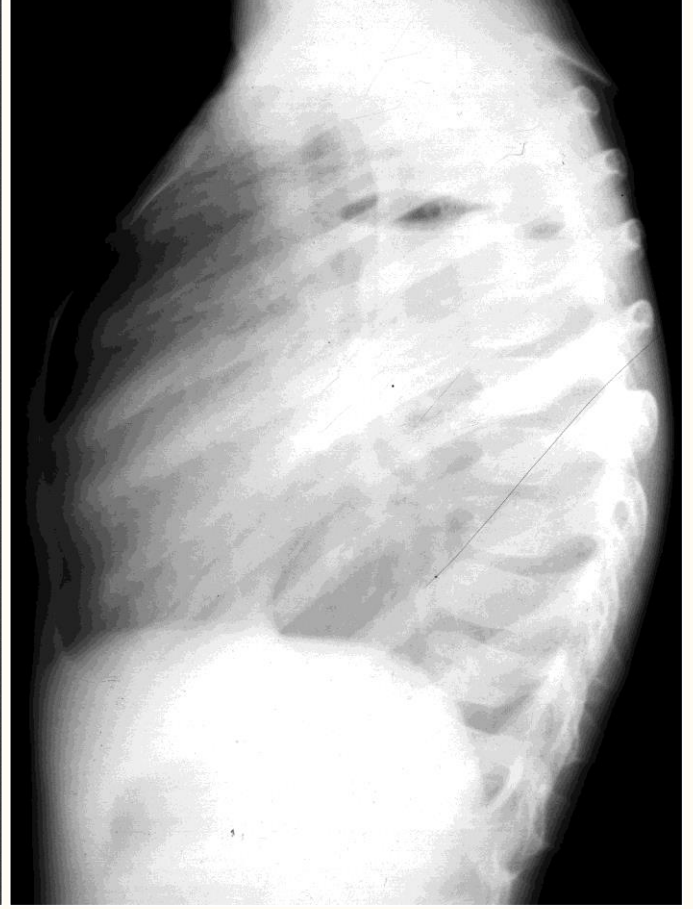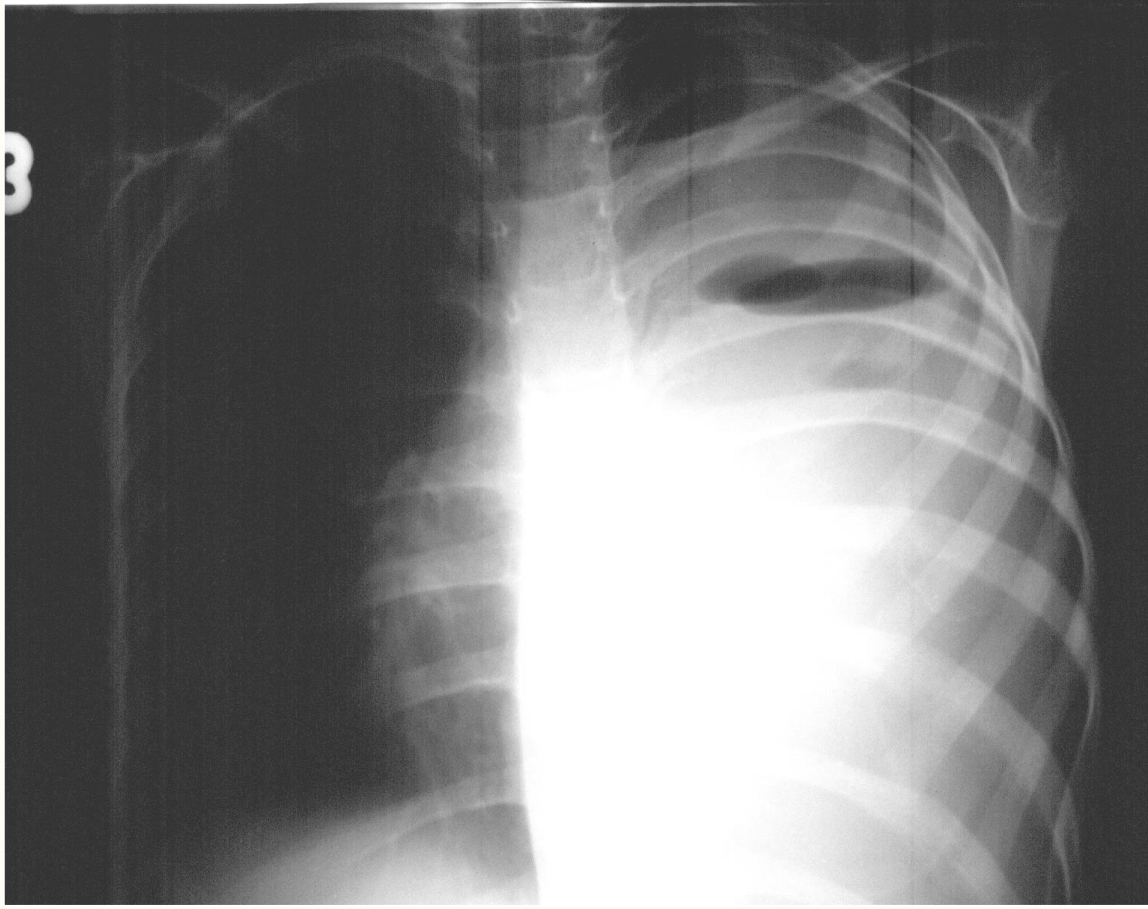


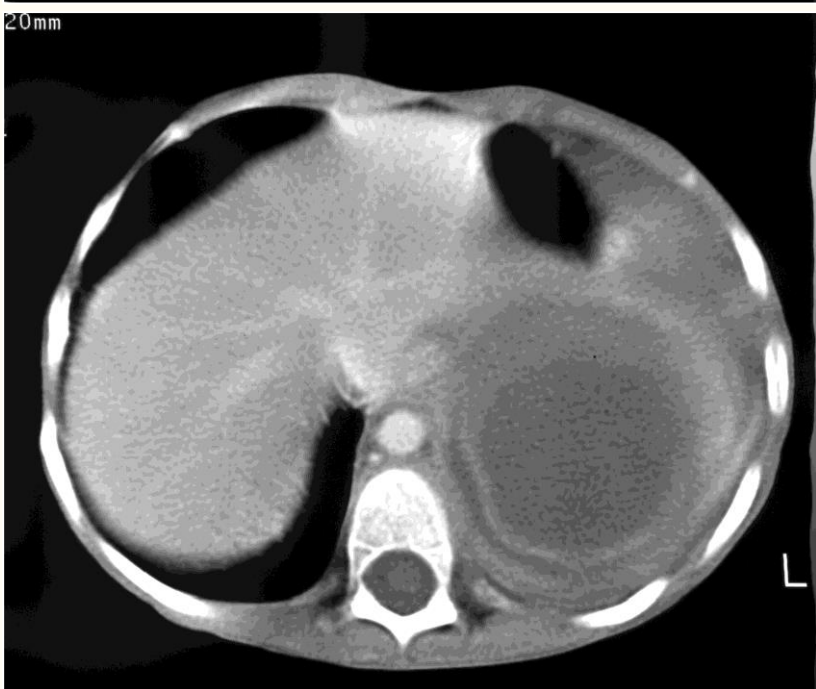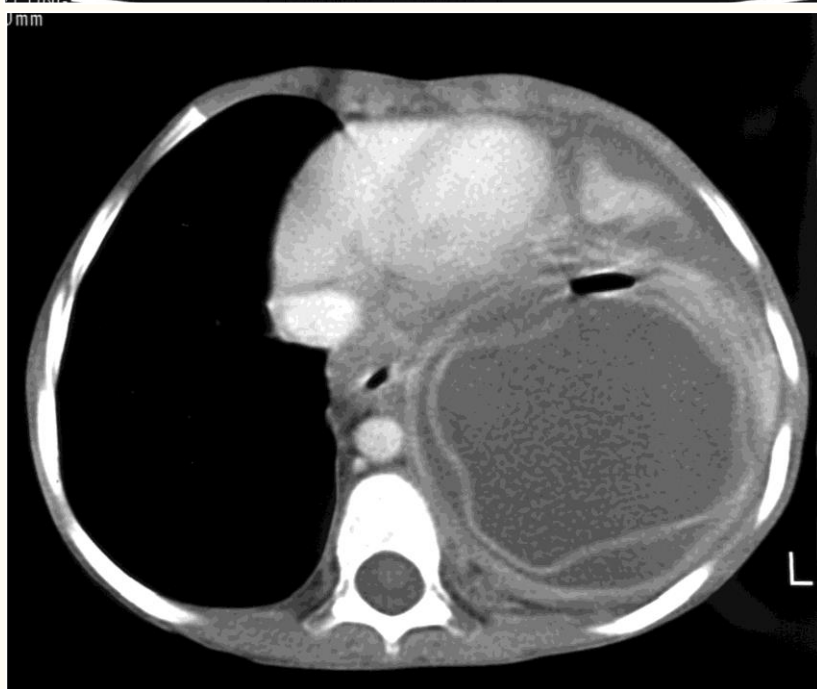
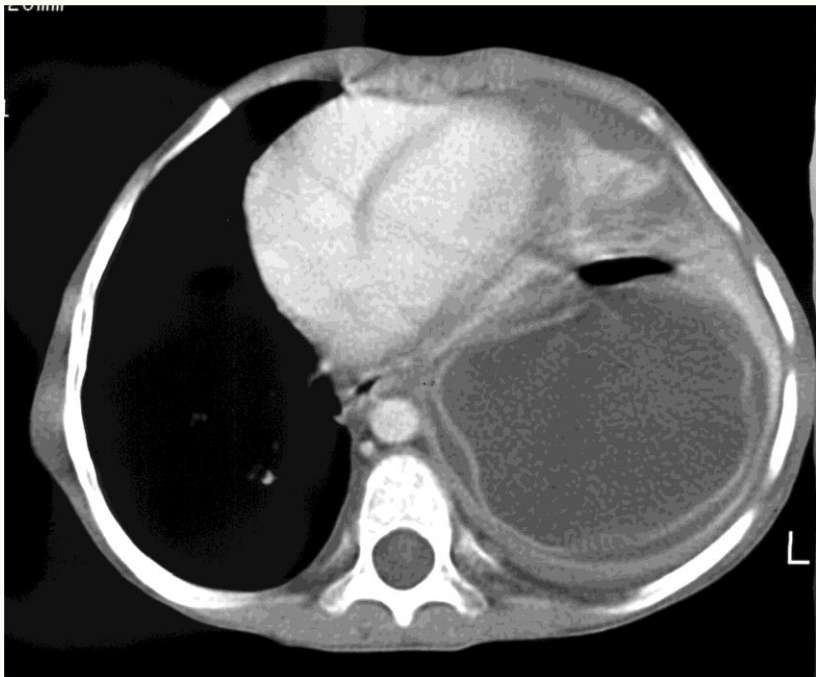
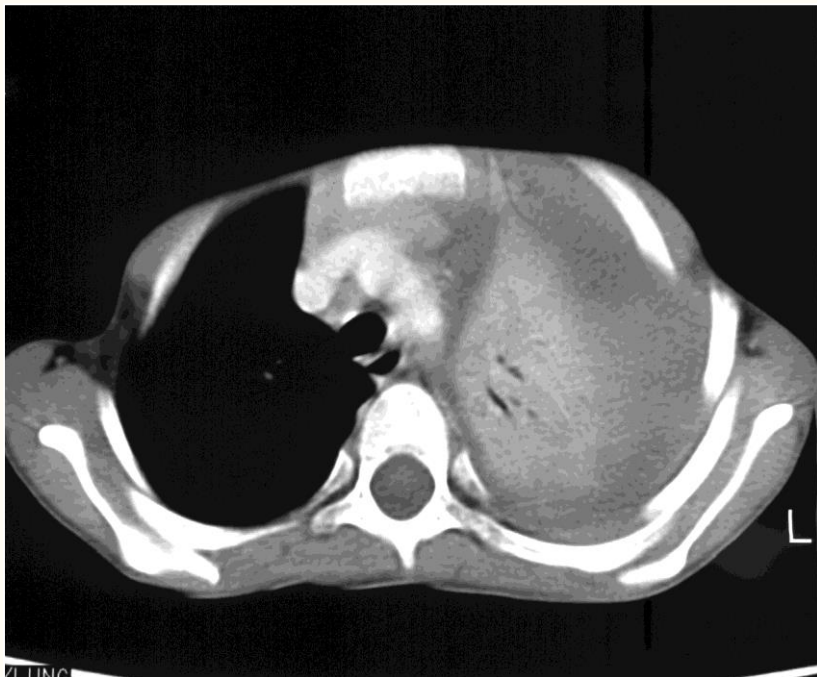


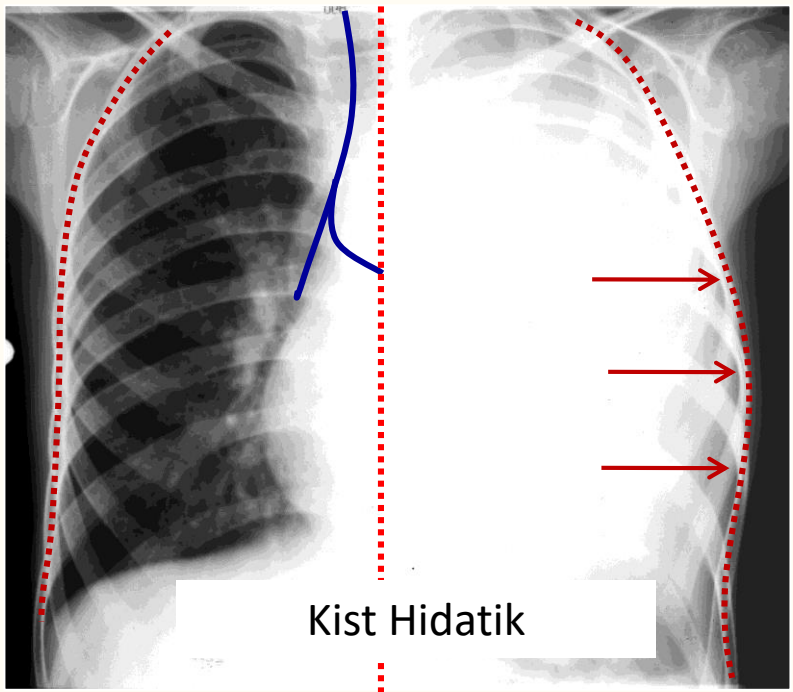
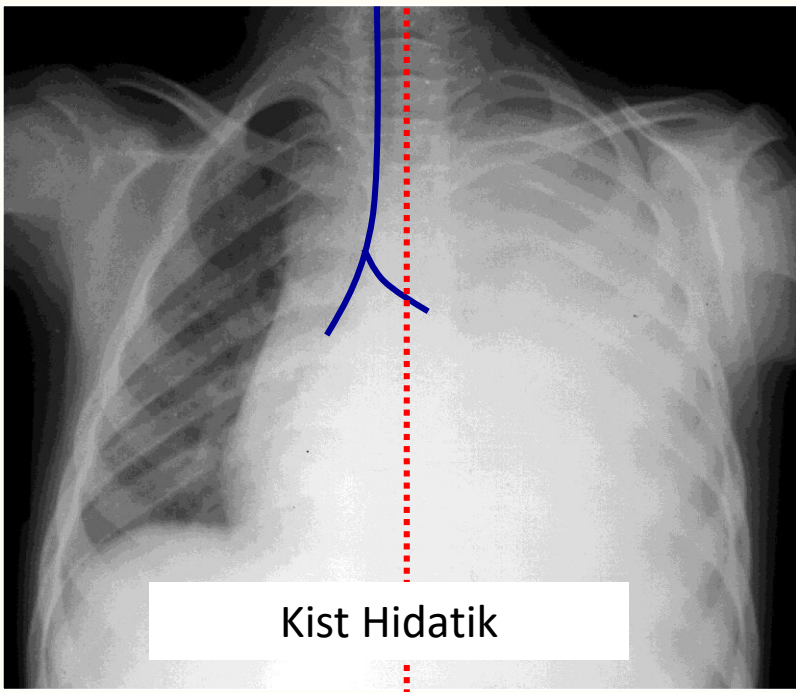
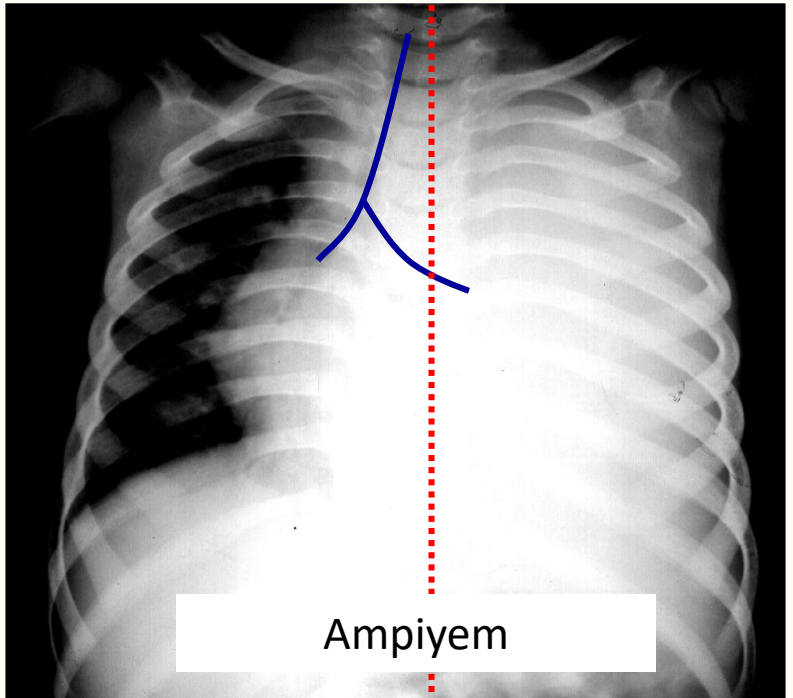
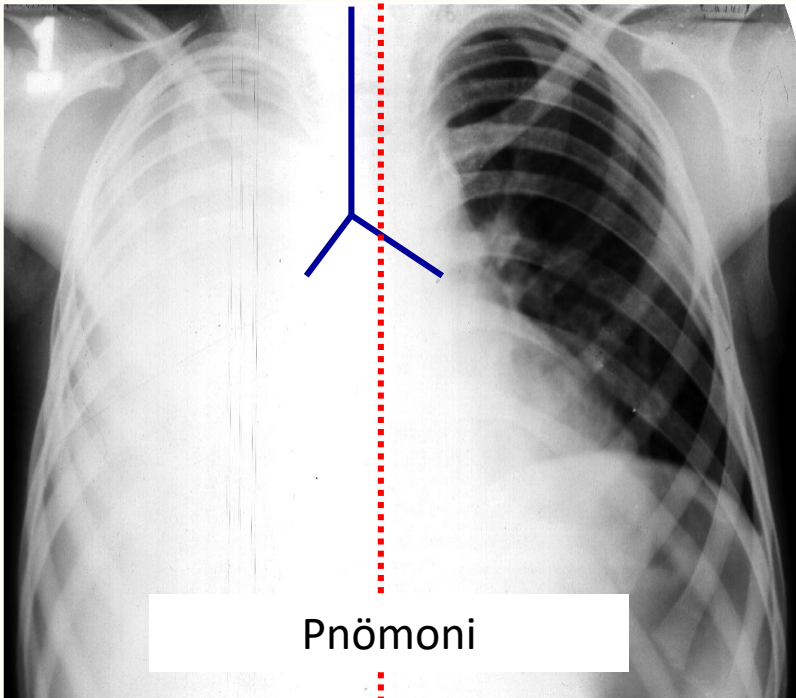












ULTRASON Endikasyonları

Yenidoğanın kardio-vasküler anomalileri (*)

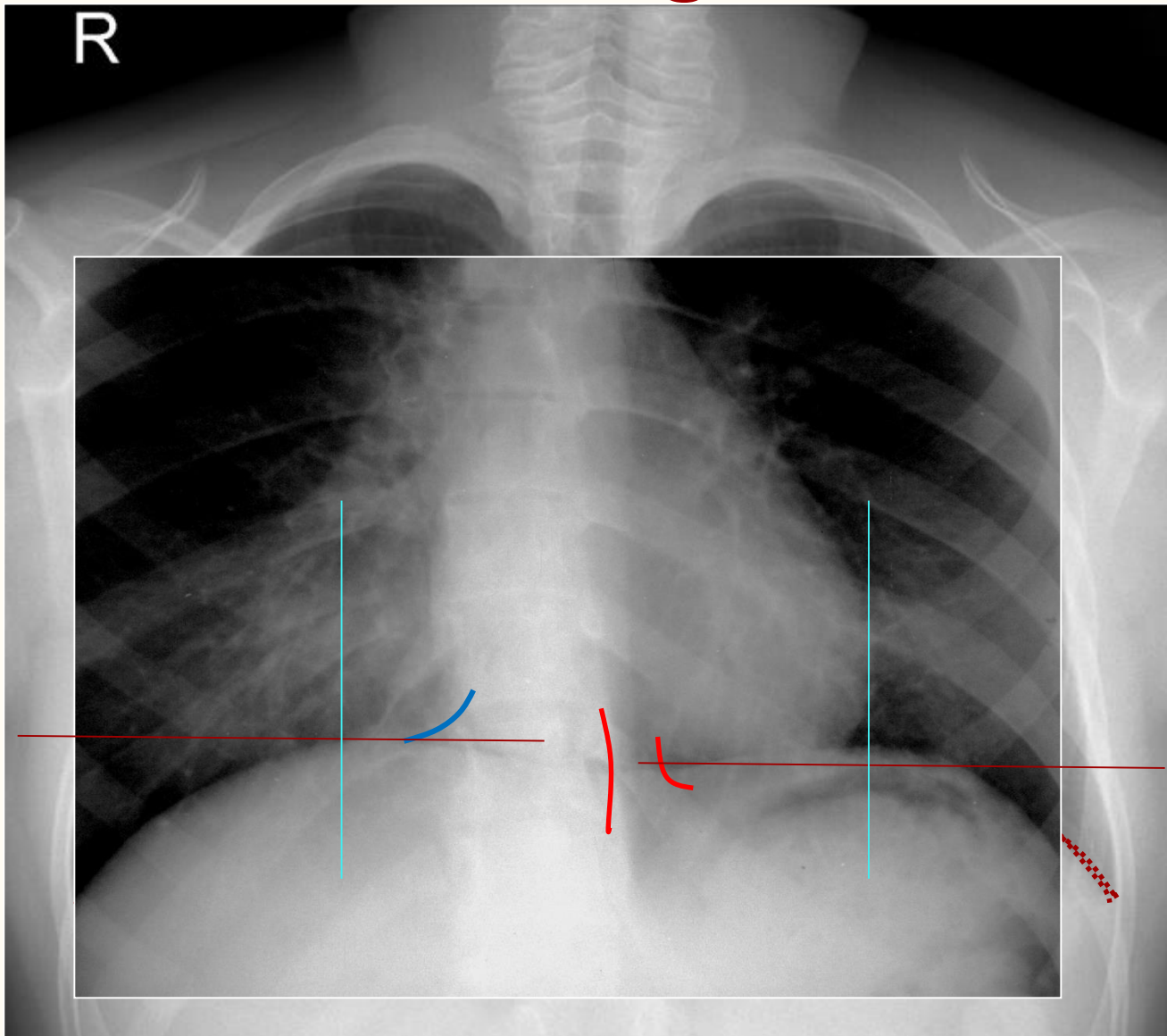
Tek taraflı opak akciğer

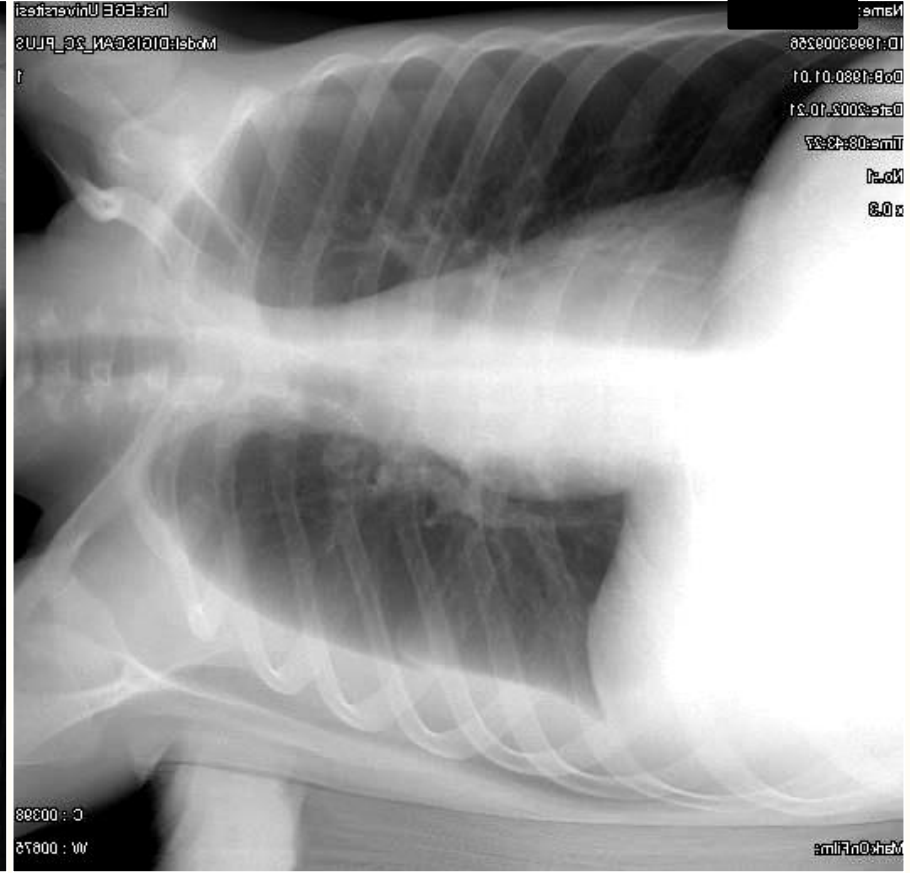
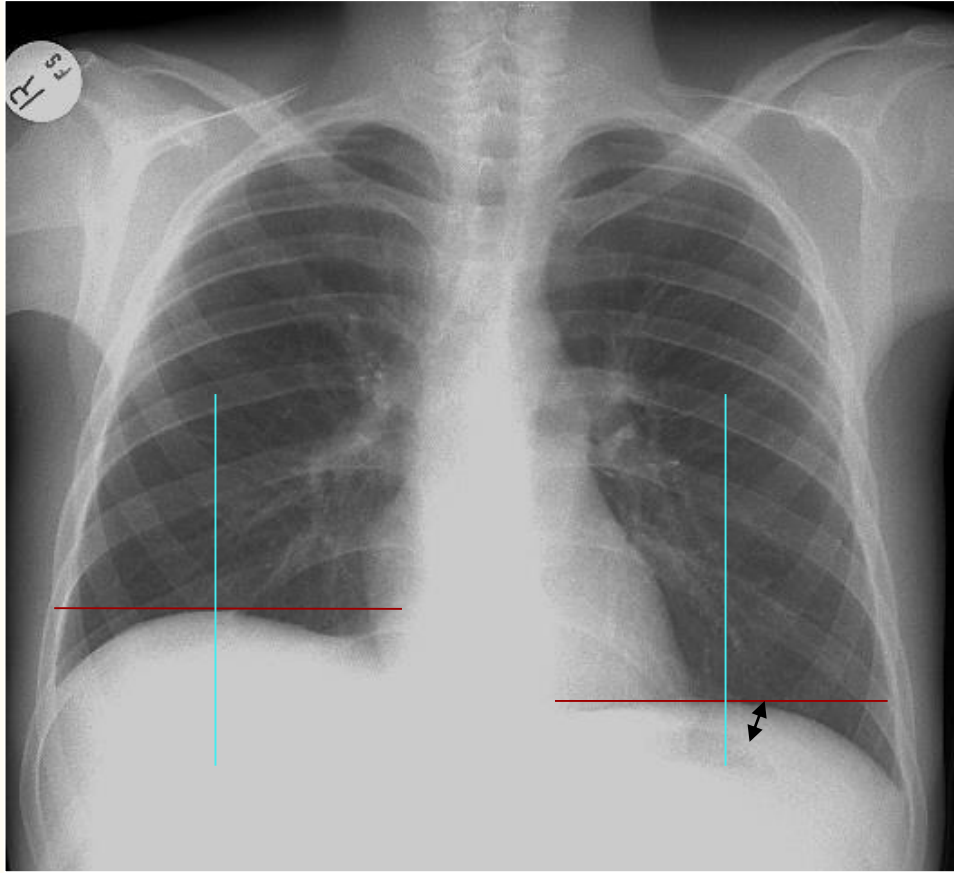
Toraks duvarına bitişik opasiteler

Plevral effüzyon

Plevral hastalıklar

Diafragma





Supine pozisyonda sıvı ve havanın toraks içinde dağılımı

